

## CASE REPORT

# GALLSTONE ILEUS: A RARE CAUSE OF INTESTINAL OBSTRUCTION

Hitendra K Desai<sup>1</sup>, Bharat C Rathva<sup>2</sup>, Prakash V Chauhan<sup>2</sup>, Rajesh D Patel<sup>1</sup>, Rajnish R Patel<sup>3</sup>

<sup>1</sup>Assistant Professor; <sup>2</sup>Third year resident; <sup>3</sup>Additional Professor, Department of Surgery, Civil hospital, Ahmedabad

## ABSTRACT

Gallstone ileus is an uncommon complication of cholelithiasis, with a high morbidity and mortality rate, usually related to the delayed diagnosis of intestinal obstruction. Diagnosing gallstone ileus needs a high index of suspicion. A case of a gallstone ileus is reported. The clinical presentation, radiological features, intra-operative findings, operative procedure and literature review are presented.

**Key words:** Gall stone, intestinal obstruction

## INTRODUCTION

Gallstone ileus is an uncommon complication of cholelithiasis, with a high morbidity and mortality rate. It constitutes 0.4% of all cholecystectomies and 3.7% of the operated small bowel obstructions.

## CASE REPORT

A 40-year-old female presented to the emergency room with a 3-week history of intermittent, colicky abdominal pain, initially localized in the right hypochondrial and peri-umbilical region, generalized later on.

Pain relieved after passing faeces initially and associated with decreased bowel movements, vomiting and abdominal distention. After two days, the abdominal pain became worse, distention increased and the patient developed an absolute obstipation.

She was admitted to Palanpur civil hospital and managed conservatively for 18 days. Patient was kept on parenteral nutrition, a nasogastric tube was inserted and enema was given twice in first week after which she passed faeces.

Routine investigations were done, including serial radiographs, ultra sonography suggestive of dilated fluid filled bowel loops with sluggish peristalsis, gall bladder collapsed, with mild free fluid in abdomen. Her condition did not improve and she was referred to Civil Hospital Ahmedabad.

Her past history included history of flatulent dyspepsia for 1 yr. history of ultra sonography done 8 months back, suggestive of presence of multiple GB calculi. Her operative history was unremarkable except for a laparoscopy as a part of investigative work up for infertility.

On examination, she was slightly tachycardic (90/min) and afebrile; her BP was 122/80; her abdomen was soft,

distended, nontender. No guarding, rigidity, organomegaly or ascites was apparent. Peristalsis was sluggish. Per rectal examination showed presence of liquid stools, rest within normal limits. Her WBC count was 15.7, Sr K+ 3.1, rest haemogram, coagulation study, renal and liver function tests were normal.

Abdominal X-ray showed distended small bowel loops with multiple air fluid levels (figure 1), chest X-ray was normal (figure 2). Ultrasonography suggestive of dilated and content filled bowel loops with sluggish peristalsis with minimal inter-bowel free fluid.

Patient was resuscitated with fluids, and a nasogastric tube was inserted. There after she was taken to an operating room. A midline incision was made. The stone was identified 20 cm proximal to ileo-caecal junction, where an enterotomy was made and the stone was extracted. The stone was 3x4 cm in size (figure3).

The bowel was explored for possibility of other stones and while emptying the proximal bowel two more stones, 2x1.5 cm and 1x1.5cm were found (figure 4). Tube drain was kept in pelvis. Gall bladder and CBD were found to be within normal limits. Post-operative recovery was uneventful except for hypokalemia which was corrected and she was discharged 13 days post-surgery

## DIAGNOSIS

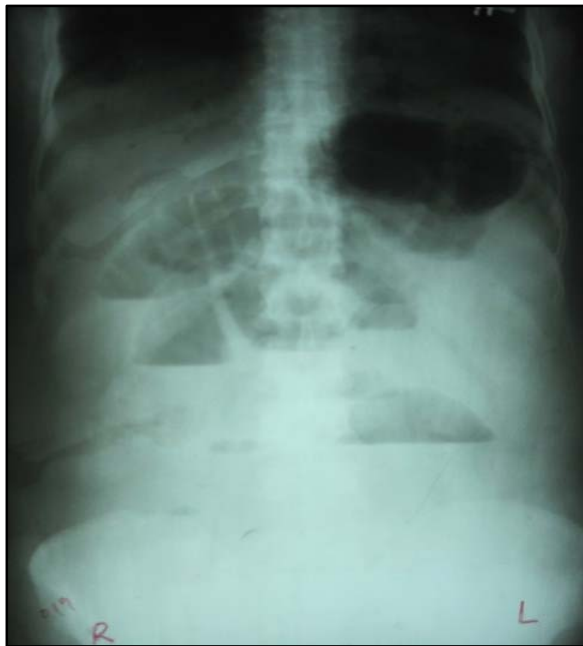In Reisner and Cohen series<sup>2</sup> correct diagnosis of gallstone ileus, confirmed at laparotomy, was made pre-operatively in 43% of the patients.

Traditionally, plain abdominal radiography remained mainstay for the assessment of small bowel obstruction. However, the sensitivity of plain film varies from 40 to 70% in diagnosing gallstone ileus.<sup>3</sup> The classical radiological features of gallstone ileus were described by Rigler et al. in 1941<sup>4</sup> and are summarized in Table 1.

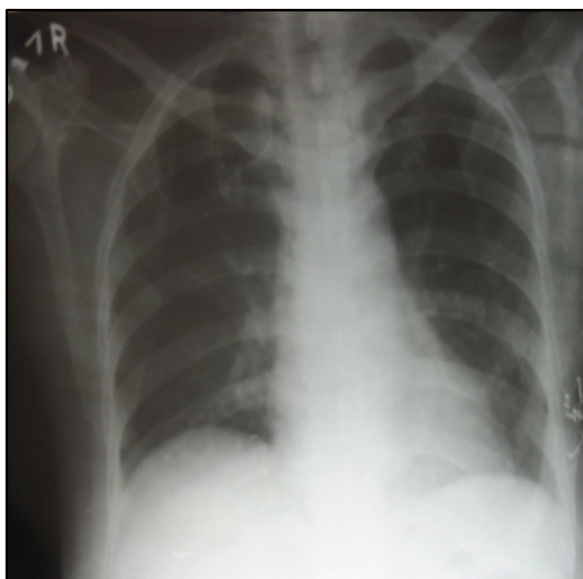
**Table 1: Radiological features of gallstone ileus on plain abdominal films**

Air (pneumobilia) or contrast medium in the biliary tree
Direct or indirect (using contrast medium) visualization of a stone in the intestine
A change in the position of a previously observed stone
Evidence of partial or complete intestinal obstruction

In this case, diagnosis of gall stone ileus was intra-operative.



**Figure 1 Abdominal radiograph in standing position**



**Figure 2 chest radiograph**



**Figure 3: Fragments of impacted stone**



**Figure 4: Other two milked out stones**

Ultrasonography has been shown to be more helpful than plain films in diagnosing gallstone ileus.<sup>5</sup> They found that abdominal sonography demonstrated bowel loop dilatation (44.44%), extraluminal fluid (14.81%), ectopic stones (14.81%), gallbladder abnormalities (37.04%), and pneumobilia (55.56%).

Diagnostic CT criteria include<sup>2</sup>, SBO,<sup>1</sup> ectopic gallstone, rim-calcified or total-calcified,<sup>3</sup> abnormal gall bladder with complete air collection, presence of air-fluid level or fluid accumulation with irregular wall.

The site of stone impaction as shown by Reisner and Cohen<sup>2</sup> was Ileum 60.5%, Jejunum 16.1%, Stomach 14.2%, Colon 4.1% and Duodenum 3.5%.

**TREATMENT**

The appropriate treatment of gallstone ileus is controversial. Both operative and nonoperative approaches have been described in the literature.

One-stage procedure (enterolithotomy plus fistula repair and cholecystectomy), when feasible, should be the first choice. The higher mortality associated with one-stage

operational though not statistically significant, warranted a procedure directed at the obstruction. Moreover, the morbidity related to the biliary tract and the biliary-enteric fistula is low [Table 3]. Even a subsequent cholecystectomy might not be needed if the patient is asymptomatic.

**Table 2: Mortality from gallstone ileus based on surgical procedure<sup>1</sup>**

Procedure	Mortality (%)
One stage	19/113 (16.9%)
Entero-lithotomy alone	94/801 (11.7%)
Non-operative	13/49 (26.5%)

**Table 3: Morbidity from gallstone ileus<sup>1</sup>**

Morbidity	Percentage
Wound infection	32
Biliary symptoms	15
Recurrence	4.7
Operation	10

In the case that we reported, the decision was made not to perform a subsequent cholecystectomy, because the patient was asymptomatic 2 months after the operation and the ultrasound showed a normal biliary tree.

The laparoscopy-assisted techniques have been reported in management of gall stone ileus.

One should remember that laparoscopy is somehow more challenging in those patients because of the dilated and edematous bowel in those cases that require gentle manipulation of the bowel to prevent perforation. Also, one should remember that incidence of second stone has been reported in 3-15% of patients, and the need to run the bowel either by the laparoscope or through a mini laparotomy is important.

The final technical issues to remember are milking the stone and making the enterotomy away from the site of impaction because it is often edematous. In addition, resection of the segment of bowel might be necessary if the stone is firmly fixed in an edematous and inflamed segment of bowel

## REFERENCES

- Pavlidis TE, Atmatzidis KS, Papaziogas BT, Papziogas TB. Management of gallstone ileus. *J Hepatobiliary Pancreat Surg* 2003;10:299-302.
- Reisner RM, Cohen JR. Gallstone ileus: A review of 1001 reported cases. *Am Surg* 1994;60:441-6.
- Maglinte DD, Reyes BL, Harmon BH, Kevlin FM, Turner WW Jr, Hagej E, et al. Reliability and role of plain film radiography and CT in the diagnosis of small-bowel obstruction. *Am J Roentgenol* 1996;167:1451-5.
- Rigler LG, Borman CN, Noble JF. Gallstone obstruction: Pathogenesis and roentgen manifestations. *JAMA* 1941;117:1753-9.
- Ripolles T, Miguel-Dasit A, Errando J, Morote V, Gomez-Abril SA, Richart J. Gallstone ileus: Increased diagnostic sensitivity by combining plain film and ultrasound. *Abdom Imaging* 2001;26:401-5.
- Yu CY, Lin CC, Shyu RY, Hsieh CB, Wu HS, Tyan YS, et al. Value of CT in the diagnosis and management of gallstone ileus. *World J Gastroenterol* 2005;11:2142-7.
- Lassandro F, Gagliardi N, Scuderi M, Pinto A, Gatta G, Mazzeo R. Gallstone ileus analysis of radiological findings in 27 patients. *Eur J Radiol* 2004;50:23-9.
- Lassandro F, Romano S, Ragozzino A, Rossi G, Valente T, Ferrara I, et al. Role of helical CT in diagnosis of gallstone ileus and related conditions. *AJR Am J Roentgenol* 2005;185:1159-65.
- Bourke MJ, Schneider DM, Haber GB. Electrohydraulic lithotripsy of a gallstone causing gallstone ileus. *Gastrointest Endosc* 1997;45:521-3.
- Sarli L, Pietra N, Costi R, Gobbi S. Gallstone ileus: Laparoscopic-assisted enterolithotomy. *J Am Coll Surg* 1998;186:370-1