

CASE REPORT

PSEUDOANEURYSM OF INTERNAL ILIAC ARTERY

Seema Khanna¹, Ajay Kumar Khanna¹, Shashi Prakash Mishra¹, Sanjeev kumar Gupta¹

Authors' Affiliation: ¹Dept of Gen Surgery, Institute of Medical Sciences, BHU, Varanasi

Correspondence: Dr. Seema Khanna, Email: seemakhanna119@rediffmail.com

ABSTRACT

An unusual cause of vaginal bleeding after total abdominal hysterectomy is being reported. Histopathology revealed adenomyosis uteri and bilateral ovarian cyst. On examination there was a single lump in the hypogastrium and left iliac fossa. Auscultation revealed a faint continuous hum. On digital rectal examination, a bulge was felt, while per vaginal examination revealed mucosal congestion and bulging of mucosa. Ultrasound revealed a mass posterior to the urinary bladder. Duplex study demonstrated the yin-yang sign suggestive of a pseudo-aneurysm. CT Angiography was confirmatory and demonstrated a pseudoaneurysm arising from the left internal iliac artery. Patient underwent surgery. Postoperative period was uneventful.

The commonest cause of IIA aneurysm is atherosclerosis. Other causes are arteritis, collagen vascular disease, infection, and trauma. An important subgroup is young females, who have undergone difficult delivery, forceps delivery or caesarian section or abdominal hysterectomy

IIA aneurysms are usually discovered incidentally on pelvic imaging for any other indication. Surgery is the mainstay of treatment but endovascular procedures are gaining ground.

Key Words: Pseudoaneurysm, CT Angiography, Internal iliac artery

INTRODUCTION

Pseudoaneurysm of the Internal Iliac Artery (IIA) is a rare complication of abdominal hysterectomy. It is also an uncommon cause of per vaginal bleed postoperatively.

CASE HISTORY

A 25 year old female presented in surgery outpatient department with history of vague lower abdominal pain and bleeding per vaginum for 2 months. She had undergone total abdominal hysterectomy and bilateral salphingoophorectomy 2 years back. The postoperative histopathology report had revealed adenomyosis uteri and bilateral ovarian cyst. Per abdominal examination revealed a single, 10 X 8 cm, smooth, globular lump in the hypogastrium, also extending into the left iliac fossa. It was firm in consistency, non-tender, non pulsatile, non-expansile. All margins were well defined except the lower margin which could not be felt as it was extending into the pelvis. Auscultation, revealed a faint continuous hum. On digital rectal examination, a bulge was felt on the anterior and left side, while per vaginum and per speculum examination revealed mucosal congestion and bulging of mucosa. Ultrasound of the abdomen revealed a mass posterior to the urinary bladder. Duplex study demonstrated the yin-yang sign suggestive of a pseudoaneurysm but the feeding vessels could not be delineated. CT Angiography was confirmatory and demonstrated a 10 X 8.9 X 9 cm pseudoaneurysm arising from the left internal iliac artery. Collaterals from the right

IIA and Inferior mesenteric artery were observed. Patient underwent exploratory laparotomy with ligation of bilateral IIA and Inferior mesenteric artery distal to emergence of its branches.(Figure 1) Aneurysmorrhaphy was not attempted, as disruption of collaterals on posterior aspect could cause hemorrhage. Post operative period was uneventful and bleeding per vaginum stopped on 2nd post operative day. Patient was discharged on postoperative day 6 on full oral diet. At 2 months follow up, the patient was well but Duplex USG had revealed only a minimal decrease in the size of the pseudoaneurysm.

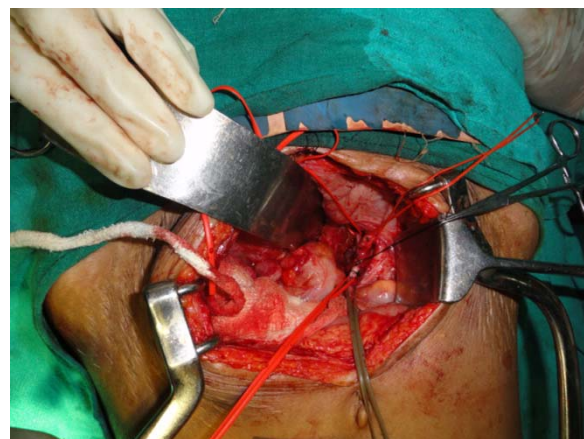


Fig 1: Operative photograph showing ligation of left Internal Iliac Artery

DISCUSSION

Iliac artery aneurysm is a permanent, localized dilatation of the iliac artery, larger than 1.5 cm in diameter as advocated by the subcommittee on Reporting standards for Arterial Aneurysms of the Society for Vascular Surgery [1]. An aneurysm of the IIA is defined as a two fold increase in the size of the artery without a co-existing aneurysm in another location [2].

The commonest cause of IIA aneurysm is atherosclerosis. Other less common causes are disorders of the arterial wall like arteritis and collagen vascular disease, infection, trauma. Trauma can be iatrogenic during hip replacement surgery, lumbar disc surgery, and pelvic surgery. Penetrating injury to the pelvis and pelvic fractures may lead to IIA aneurysm. An important subgroup of patients is young females, who have undergone pregnancy and difficult delivery, forceps delivery or caesarian section or abdominal hysterectomy [2].

IIA aneurysms are usually discovered incidentally on pelvic imaging for any other indication. Only 50% of patients may be symptomatic presenting with vague lower abdominal and flank pain, pyelonephritis and sepsis from ureteral obstruction, paraesthesias of lower extremities due to pelvic nerve compression. As the signs and symptoms are not directly attributable to the vascular system, the diagnosis is often delayed[3]. CECT scan provides accurate localization of the feeding artery and also excludes the presence of other intra-abdominal aneurysms.[4]

Surgery involving the proximal \pm distal ligation of the feeding vessels had been the mainstay of treatment but with the upcoming trend towards minimal access surgery, endovascular procedures like embolization, endoaneurysmorrhaphy and endoluminal stenting are gaining ground and are established to be safe and effective. Over all perioperative mortality is high (33 – 50%) in emergency setting while it reduces to 7 – 11% for elective procedures.[5] Current recommendations favour elective repair in aneurysms measuring >3.5 cm in healthy patients. For sizes smaller than this, serial follow up with B-mode ultrasound or CT imaging is recommended. [6]

As the visceral branches of IIA supply the urinary bladder, rectum, prostate, seminal vesicles, ejaculatory ducts

in males and the gonads, uterus, vagina, urinary bladder and urethra in females along with gluteal region, posterior and antero-medial regions of thigh and hip joint, the bilateral ligation may cause buttock claudication, bladder sphincter dysfunction, colorectal ischaemia, ischaemic injury to lumbosacral plexus in elderly patients, vasculogenic impotence in males. However, our patient did not have any such problem in the postoperative period.

CONCLUSION

We have reported an unusual cause of pervaginal bleeding following abdominal hysterectomy in a young female. The underlying cause was a pseudoaneurysm of the internal iliac artery which being a very unusual complication of abdominal hysterectomy is difficult to diagnose clinically. CT scan particularly CT angiography is confirmatory. In view of the multiplicity of feeding vessels, the management of these cases is difficult as resectional surgery may lead to massive intraoperative bleeding. Endovascular procedures are a good alternative provided expertise is available.

REFERENCES

1. Johnston KW, Rutherford RB, Tilson MD et al. Suggested standards for reporting on arterial aneurysms. Sub Committee on Reporting Standards for Arterial Aneurysms, Ad Hoc Committee on Reporting Standards, Society for Vascular Surgery and North American Chapter, International Society for Cardiovascular Surgery. *J Vasc Surg* 1991; 13 : 452 – 458
2. Dix FP, Titi M, Al-Khaffaf H. The Isolated Internal Iliac Artery Aneurysm – A Review. *Eur J Vasc Endovasc Surg* 2005 ;30: 119 – 129.
3. Sandhu R.S., Pipinos I.I. Isolated Iliac Artery Aneurysms. *Seminars in Vascular Surgery*. 2005;209-215.
4. Sen S, Mills MS, Andrews HS. Pseudoaneurysm of the internal iliac artery following vaginal hysterectomy. *International Journal of Gynecology and Obstetrics*. 2012 (Article in press).
5. Richardson JW, Greenfield LJ. Natural history and management of iliac aneurysms. *Vasc Surg* 1988; 8 : 165 – 171.
6. Santilli SM, Wernsing SE, Lee ES : Expansion rates and outcomes for iliac A aneurysms. *J Vasc Surg*.2000; 31 : 114 – 121