

## CASE REPORT

# ACUTE PANCREATITIS DUE TO RUPTURE OF THE HYDATID CYST INTO THE BILIARY TRACT: A CASE REPORT

Zülfü Bayhan<sup>1</sup>, Sezgın Yılmaz<sup>2</sup>, Çağrı Tıryakı<sup>3</sup>, Ertugrul Kargı<sup>4</sup>, Bercis Imge Ucar<sup>5</sup>

**Authors' Affiliation:** <sup>1</sup>Dumlupınar University, Faculty of Medicine, Department of General Surgery, Kutahya, Turkey; <sup>2</sup>Afyon Kocatepe University, Faculty of Medicine, Department of General Surgery, Afyon, Turkey; <sup>3</sup>Kocaeli Derince Training and Research Hospital, Department of General Surgery, Kocaeli, Turkey; <sup>4</sup>Abant İzzet Baysal University, Faculty of Medicine, Department of General Surgery, Bolu, Turkey; <sup>5</sup>Dumlupınar University, Faculty of Medicine, Department of General Surgery, Kutahya, Turkey

**Correspondence:** Ertugrul Kargı, Email: drekargi@yahoo.com.tr

## ABSTRACT

Hydatid disease is still endemic in our country and in many parts of the world. Liver is the most common site of hydatid disease. Rupture of hydatid cysts of liver into the biliary ducts can be seen as a complication. Obstructive jaundice, acute cholangitis and much more rarely acute pancreatitis may occur due to rupture of hydatid cysts into the biliary ducts. In this case report, a 38-year-old male patient with findings of acute pancreatitis and obstructive jaundice due to rupture of hydatid cyst into the biliary tract were presented. In our case, Endoscopic retrograde cholangiopancreatography (ERCP) was performed to the patient with diagnostic and therapeutic purposes. Parts of germinative membrane located within the common bile duct and causing the obstruction of papillary orifice was seen in ERCP. Germinative membrane components were removed during the process. Endoscopic sphincterotomy was performed to the patient. After the procedure, the clinical findings and laboratory findings of the patient returned to normal rapidly. As a result, it should be noted that rupture of hepatic hydatid cysts into the bile ducts might be a rare cause of biliary pancreatitis. It must be kept in mind that endoscopic sphincterotomy and endoscopic removal of cyst membranes is a very important method for the diagnosis and treatment of the acute pancreatitis and obstructive jaundice due to rupture of hydatid cyst into the biliary tract.

**Keywords:** Hydatid cyst, Hydatid disease of the liver, Pancreatitis, Rupture to the biliary tract, Obstructive Jaundice

## INTRODUCTION

Hydatid Cyst is an endemic disease in many countries of the world caused by a parasite named *Echinococcus Granulosus*. Liver is the most common site of hydatid cyst. Lung involvement can also be observed. Though rarely, the disease may involve spleen, kidneys, brain, muscles, bones and pancreas (1,2). Clinical symptoms may take various forms subject to anatomic location of the cyst. Rupture of hydatid cyst of the liver into bile ducts can be seen as a complication. Obstructive jaundice, acute cholangitis and much more rarely acute pancreatitis may occur due to rupture of hydatid cysts into the biliary ducts (3). In our case, it was shown that the hydatid cyst of the liver can extend to the bile duct and impact the papillary orifice, resulting in acute pancreatitis and obstructive jaundice.

## CASE REPORT

A 38-year-old male patient consulted the emergency department due to pain in the right upper quadrant of the abdomen radiating towards the dorsum and pain in epigastric region, suffered for the last 24 hours, accompanied by fever and nausea-vomiting. The patient had a history of hydatid cyst of the liver, and had, about 2

years ago, undergone 3 sessions of percutaneous cyst aspiration, scolocidal agent injection and drainage with the PAIR method for approximately 5 weeks, and in addition to this invasive treatment, albendazole therapy was applied as a medical treatment.

In the physical examination, blood pressure was 120/80 mmHg, pulse rate was 85/min, and body temperature was 37.3 °C. In abdominal examination, there was sensitivity in epigastric region and upper right quadrant. Defense and rebound were absent. Abnormal laboratory findings remarkable in terms of acute pancreatitis were as follows: WBC 13.3 1000/ $\mu$ l, AST 546 U/L, ALT 289 U/L, T.BIL 2.76 mg/dL, D.BIL 2.12 mg/dL, LDH 863 U/L, Amilase 1150 U/L, Lipase 795 U/L, GGT 473, CRP 2.31 mg/dL. In IV contrast-enhanced abdominal CT and abdominal ultrasonography of the patient performed the same day, the size of the gall bladder was normal, with wall thickness diffusely increased and diameter of the choledoc widened (9 mm). While the views of the choledoc lumen could be meaningful in terms of gallbladder sludge, there were millimetric echogenicities that suggested the rupture of hydatid cyst into bile ducts in the differential diagnosis. Slightly dilated intrahepatic bile ducts were observed. A lesion compatible with grade 3-4 hydatid cyst approximately 42 mm x 42 mm in diameter was observed in the junction of the

segments 7/6 of the right lobe of the liver. The condition was found to be compatible with acute pancreatitis (Figure-1,2).

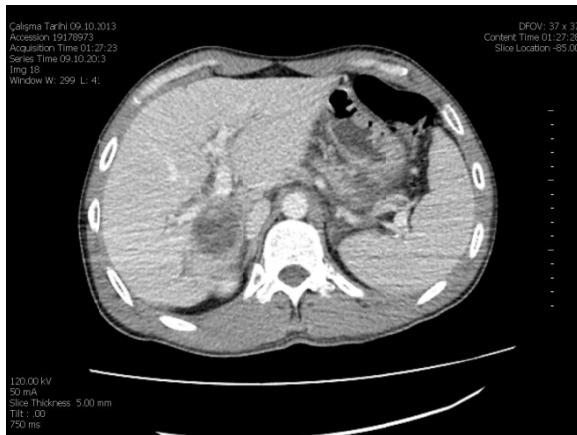

Figure 1.1: Lesion compatible with grade 3-4 hydatid cyst adjacent to intrahepatic bile ducts in the junction of segments 7-6 of the right lobe of the liver in Intravenous Contrast-enhanced Computerized Tomography of the Abdomen

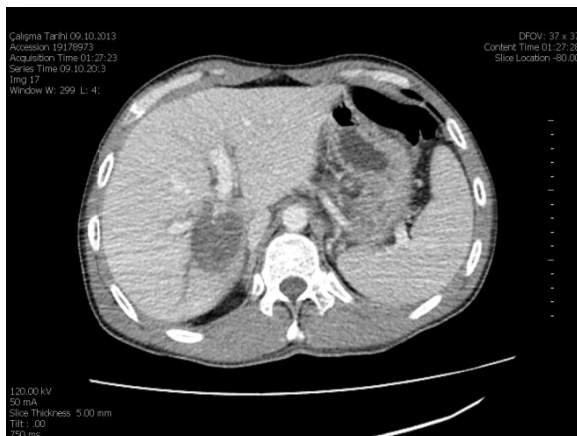

Figure 1.2: Lesion compatible with grade 3-4 hydatid cyst adjacent to intrahepatic bile ducts in the junction of segments 7-6 of the right lobe of the liver in Intravenous Contrast-enhanced Computerized Tomography of the Abdomen

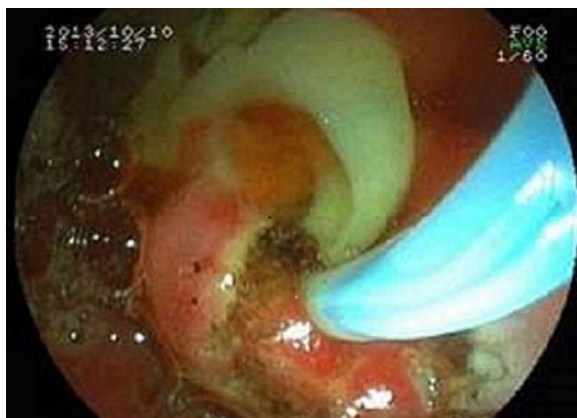

Figure 3: Germinative Membrane removed after endoscopic sphincterotomy

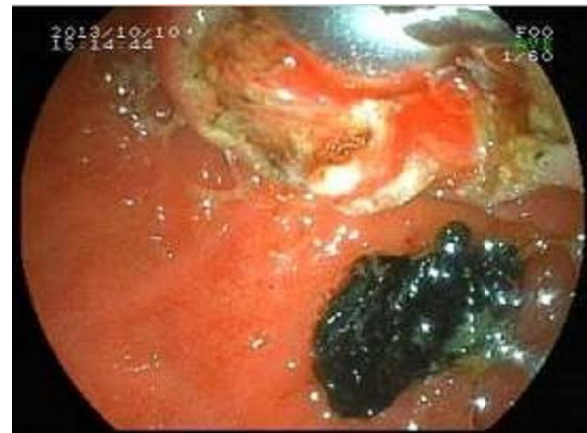

Figure 4: Bile-stained germinative membrane pieces dropped to the duodenum as a result of cleaning of the choledoc by means of basket and balloon

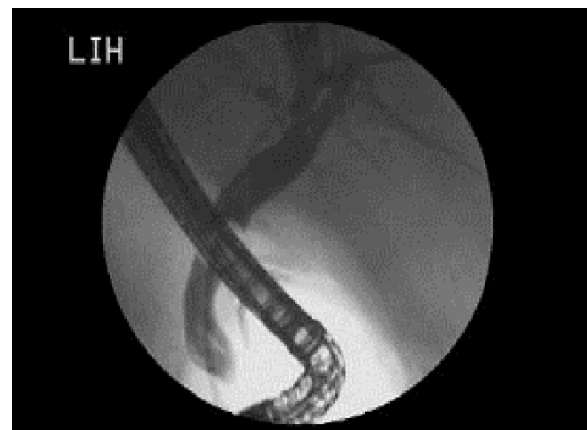


Figure 5: Appearance of the choledoc and intrahepatics in ERCP

The patient was hospitalized in the general surgery department with pre-diagnosis of acute pancreatitis. Oral nutrition was discontinued and intravenous fluid therapy was started. Antibiotic therapy was initiated and as a result of assays and physical examinations performed the next day, it was planned to perform Endoscopic Retrograd Cholangiopancreatography (ERCP) for diagnosis and treatment purposes because the clinical symptoms of the patient which were re-evaluated continued to exist and abnormal values remained high in laboratory tests. As a result of ECRP performed at an external site, it was seen that the choledoc was 11-12 mm wide and the lumen was full of diffuse densities. Endoscopic sphincterotomy was performed and choledoc was started to be cleaned by means of baskets and balloons. Several germinative membranes of the hydatid cyst were dropped to the duodenum by means of the basket. After the removal of germinative membranes, the choledoc was swept by means of the balloon, and in the radiography performed for controlling purposes, no further filling defect was seen in the choledoc (Figures 3, 4, 5).

After the ERCP procedure, the patient was again admitted to our clinic. His follow-up process was normal. The clinical symptoms fully resolved. Abnormal laboratory

findings also returned to normal. The echinococcus Indirect Hemagglutination test used in the follow-up of the patient resulted negatively. Thereupon, the patient was admitted to a follow-up program that covered physical examination, radiological and laboratory tests, and was discharged with the advice to return for control.

## DISCUSSION

In humans, hydatid cyst may remain asymptomatic until it suppresses surrounding tissues subject to its development. Cysts may at the same time extend to the peritoneal cavity or thoracic cavity and result in anaphylactic shock or formation of further multiple cysts inside the cavities (4). The rupture of a hepatic hydatid cyst spontaneously into the bile ducts is seen in 1 to 25% of all cases, and clinically, may occur with findings of cholangitis such as abdominal pain, fever and jaundice (1,5). Serology can be used to confirm diagnosis of hydatid cyst, but a negative serologic result does not rule out the diagnosis. There was negative serology in 50% of the patients (6).

The mechanism of acute pancreatitis that develops secondary to hydatid cyst is not well-established. According to us, the development of acute pancreatitis as a consequence of the elevated pressure in the pancreatic channel due to reflux into the pancreatic channel of bile and cystic material that forms after the mechanic obstruction of the papillary orifice, which develops secondary to rupture of the hepatic hydatid cyst into the bile ducts, may be responsible for the etiology. The fact that the symptoms of acute pancreatitis and obstructive jaundice rapidly return to normal after the elimination of hydatid cyst membranes and cyst contents following endoscopic sphincterotomy supports our view that acute pancreatitis develops secondary to the mechanic obstruction in the etiology. The literature includes studies with results similar to ours with regards to development of acute pancreatitis due to hepatic cyst hydatid (7, 8).

The ideal approach to the treatment of hepatic hydatid cyst is still under discussion. Although surgical intervention is a recommended approach, if complications exist and surgical access is difficult, treatment options alternative to surgical treatment include medicinal treatment and the PAIR method which includes percutaneous aspiration of the cyst, followed by injection of scolocidal agent and reaspiration of the cyst (9). The surgical option is dependent upon several options such as the number and location of cysts, the experience of the surgeon and the presence of complications (10). Endoscopic sphincterotomy is an effective, safe and well-known method in the treatment of hydatid cysts ruptured into bile ducts (11). Albendazole is the most potent anthelmintic drug used in the medical treatment in combination with surgical or percutaneous interventions. However, it may be used as the primary treatment in patients with severe accompanying diseases, patients with very small or asymptomatic cysts, or patients with multiple cysts, or patients with difficult surgical access.

In addition, it can be used as a primary treatment in patients who do not accept surgical treatment (12, 13).

## RESULTS

In our case report, there was acute pancreatitis and obstructive jaundice associated with mechanical obstruction of hydatid membranes in the papillary orifice after the rupture of hydatid cyst into the bile ducts. ERCP was applied to our patient. During the procedure, endoscopic sphincterotomy and endoscopic removal of cyst membranes were performed. After the procedure, the clinical condition and laboratory values of the patient recovered rapidly. This case report shows that endoscopic sphincterotomy and endoscopic removal of cyst membranes represent a quite effective method in patients with acute pancreatitis and obstructive jaundice caused by the rupture of hepatic hydatid cyst into the bile ducts.

## REFERENCES

1. Ammann RW, Eckert J: Cestodes. Echinococcus. *Gastroenterol Clin North Am* 1996;25:655-689.
2. Abdullah Güneş, Ertuğrul Karğı, Tuna Barış Budak, Zafer Utkan. Giant uterine cyst hydatid: A case report. *Case Report Int J Med Sci Public Health*. 2014; 3(1)
3. Cakır OO, Ataseven H, Demir A. Hydatid acute pancreatitis. *Türkiye Parazitol Derg*. 2012;36(4):251-3. doi: 10.5152/tpd.2012.59.
4. Mouaqit O, Hibatallah A, Oussaden A, Maazaz K, Taleb KA. Acute intraperitoneal rupture of hydatid cysts: a surgical experience with 14 cases. *World J Emerg Surg*. 2013 Jul 26;8(1):28. [Epub ahead of print]
5. Erzurumlu K, Dervisoglu A, Polat C, Senyurek G, Yetim I, Hokelek M. Intrahepatic rupture: an algorithm in the treatment of controversial complication of hepatic hydatidosis. *World J Gastroenterol* 2005; 11: 2472-6.
6. Parija SC: A review of some simple immunoassays in the serodiagnosis of cystic hydatid disease. *Acta Trop* 1998;70:17-24.
7. Zeytinlu M, Coker A, Yüzer Y, Ersöz G, Aydın A, Tekeşin O, Özütemiz O, Batur Y. Hydatid acute pancreatitis. *Turk J Gastroenterol*. 2004 Dec;15(4):229-32.
8. Katsinelos P, Chatzimavroudis G, Fasoulas K, Kamperis E, Katsinelos T, Terzoudis S, Kokonis G, Patsis I. Acute pancreatitis caused by impaction of hydatid membranes in the papilla of Vater: a case report. *Cases J*. 2009 Jul 7;2:7374. doi: 10.4076/1757-1626-2-7374.
9. Rajesh R, Dalip DS, Anupam J, Jaisiram A. Effectiveness of puncture-aspiration-injection-reaspiration in the treatment of hepatic hydatid cysts. *Iran J Radiol*. 2013 Jun;10(2):68-73. doi: 10.5812/iranjradiol.7370. Epub 2013 May 20.
10. Ramia JM, de la Plaza R, Casares M, Ramiro C, Veguillas P, Quiñones J, et al. Profile of patients with hepatic hydatid disease not treated surgically. *Rev Esp Enferm Dig* 2011;103(9):448-52.
11. Ozaşlan E, Bayraktar Y: Endoscopic therapy in the management of hepatobiliary hydatid disease. *J Clin Gastroenterol* 2002;35: 160-174
12. Nahmias J, Goldsmith R, Soibelman M, el-On J. Three-to-7-year follow-up after albendazole treatment of 68 patients with cystic echinococcosis (hydatid disease). *Ann Trop Med Parasitol* 1994;88:295-304.
13. Stojkovic M, Zwahlen M, Teggi A, Vutova K, Cretu CM, Virdone R, et al. Treatment response of cystic echinococcosis to benzimidazoles: a systematic review. *Trop Dis* 2009;3:524