

## CASE SERIES

# DIAGNOSIS OF STRONGYLOIDES *STERCORALIS* BY STOOL MICROSCOPY: SCREENING TOOL IN HIGH-RISK PATIENTS

Rakesh K. Babariya<sup>1</sup>, Arunima Banerji<sup>2</sup>, Ashwini B. Jajee<sup>3</sup>

**Author's affiliation:** <sup>1</sup>Resident; <sup>2</sup>Professor & Head; <sup>3</sup>Associate Professor, Pathology Department, Surat Municipal Institute of Medical Education & Research (SMIMER), Surat, Gujarat.

**Correspondence:** Dr. Arunima Banerji, Email: drab2002in@yahoo.co.in

## ABSTRACT

*Strongyloides stercoralis* an intestinal nematode, causes the disease Strongyloidiasis, which is defined by acute manifestation, autoinfection and hyperinfection leading to persistent and fatal disseminated infections in immunocompromised hosts. Effective treatment is dependent on early detection of larvae in stool. Diagnosis of *Strongyloides stercoralis* by stool microscopy has been done in two known cases of PLWH and one case of chronic alcoholic presented at SMIMER hospital. Early diagnosis is a real challenge; therefore high index of suspicion is required to get immunocompromised patients with high eosinophil count screened for *Strongyloides stercoralis* by stool microscopic examination. It is associated with high mortality rate, hence definitive and an early diagnosis is required to start appropriate therapy.

**Keywords:** *Strongyloides stercoralis*, Intestinal nematode, Immunocompromised hosts

## INTRODUCTION

Among helminths, *Strongyloides stercoralis* is a soil-dwelling nematode with a worldwide distribution, especially in tropical and subtropical countries, affecting probably 100 million humans<sup>1</sup>. It has the unique ability to maintain two different reproductive life cycles. One external, involving soil-dwelling free-living worms and another internal, involving parasitic worms within its human (definitive) host. Free-living female and male adult worms copulate in the soil, producing eggs from which rhabditiform larvae hatch. These develop into female or male adults and establish an external sexual life cycle or differentiate into the infective filariform larvae. Humans contract strongyloidiasis by penetration of these filariform larvae into the skin or mucous membranes after contact with contaminated soil. These filariform larvae enter the circulatory (venous) system, get transported to the lungs and enter the alveolar spaces. Thereafter, ascend the bronchi, trachea and pharynx. Subsequently, they are swallowed, thus reaching their final habitat in the small intestine where they become adults. Besides this migratory pathway, they may also travel through a direct route from skin to duodenum<sup>1</sup>.

In the small intestine, the parthenogenetic female adult burrows into the mucosal tissues, matures, and lays its eggs, from which rhabditiform larvae hatch. These are passed in the faeces to continue the external life cycle. But they may also develop into infective filariform larvae within the human host, which then penetrate either the perianal skin or the intestinal mucosa, with or without a subsequent passage through the lungs. This phenomenon is called autoinfection and explains why *S.*

*stercoralis* may remain asymptomatic or produce clinical symptoms in an intermittent fashion, long after the host leaves a region of endemicity<sup>1</sup>.

A life-threatening condition occurs in cases of immunosuppression by extensive tissue invasion known as hyperinfection. In this state, larval penetration through the intestinal wall may lead to sepsis and pyogenic meningitis by transporting gut bacteria into the bloodstream<sup>1</sup>.

## CASE 1

A 35 year male, a known case of PLWH presented with complaints of fever, diarrhea and weakness since one week.

Lab findings: CD4 count was 93/ $\mu$ L, Hb- 9 gm%, Total leucocyte count-5,400/cu mm, Platelet count-10,000/cu mm. Differential count showed 25% Eosinophils. Clinicians suspected of malaria or dengue fever, but investigations were negative for both. A routine stool examination was done as the patient had diarrhea. Occult blood was positive and Rhabditiform larvae of *Strongyloides stercoralis* were observed at the first glance on microscopy. The patient was treated with Albendazole & Ivermectin and he recovered with normal lab findings within four days.

## CASE 2

A 25 year male, a known case of PLWH was admitted with complaints of fever & diarrhoea. Lab investiga-

tions: Hb- 3.8 gm%, Total leucocyte count-5,700/cu mm, Platelet count-71,000/cu mm. Peripheral smear was positive for Plasmodium falciparum gamete. CD4 counts were not done. Stool examination showed posi-

tivity for occult blood and Rhabditiform larvae of Strongyloides stercoralis was observed on microscopy. He recovered with normal lab findings within five days of treatment with Ivermectin.

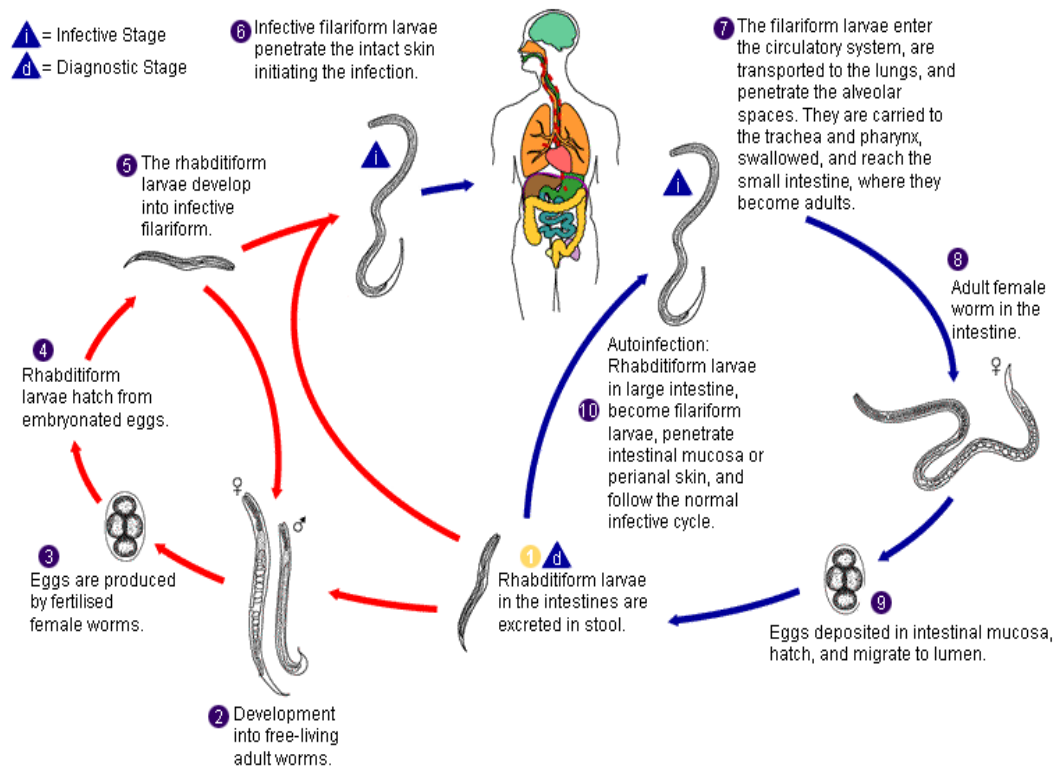


Fig: Life-cycle of Strongyloides stercoralis<sup>6</sup>

**CASE 3**

A 45 year male, a chronic alcoholic presented with fever & diarrhoea. Lab results: Hb- 7 gm%, Total leucocyte count-12,100/cu mm, Platelet count-4,00,000/cu mm, ESR was raised(54mm /1<sup>st</sup> hour). Investigations were negative for malaria & HIV. Stool for occult blood was positive and microscopic examination revealed Rhabditiform larvae of Strongyloides stercoralis. He was treated with Albendazole and there was recovery within five days.

Saline & Iodine-stained faecal smears were prepared from fresh stool specimens of all the three patients for microscopic examination.

**DISCUSSION**

Strongyloides stercoralis is endemic in tropical and subtropical zones. Warm moist temperatures, lower socioeconomic status and poor sanitation leading to faecal contamination of soil have contributed to the increased prevalence of strongyloidiasis in the tropics<sup>2</sup>. Several risk factors are associated with Strongyloidiasis like immunosuppressive therapy for rheumatic disease, malignancy (especially lymphomas), solid organ and haematological stem cell transplants<sup>2</sup>. Some immunocompromised patients with Human immunodeficiency virus

(HIV) infection, Diabetes mellitus, hypochlorhydria, alcoholism, tuberculosis, impaired bowel motility, malnourishment, chronic obstructive pulmonary disease, leprosy, chronic renal failure and other chronic diseases, which included hepatitis, chronic heart disease, chronic pancreatitis and mucormycosis have also shown association with Strongyloidiasis<sup>2</sup>.

The simultaneous presence of rhabditiform and filariform larvae in stool samples may microscopically prove the state of *S. stercoralis* autoinfection<sup>1</sup>. The hyperinfection syndrome is manifested mainly by gastrointestinal and pulmonary symptoms<sup>3,4</sup>. Dysentery, paralytic ileus, pulmonary insufficiency, bacterial meningitis, encephalitis and brain abscess can develop. All these may result in multiple organ failure and death.

Rhabditiform larva of Strongyloides stercoralis was diagnosed in three cases on stool microscopy. In one of the presented cases of PLWH, CD4 count was very much decreased & had high eosinophilic count with stool positive for occult blood. Another case of PLWH was positive for malaria with occult blood positive in stool. Strongyloidiasis is common in HIV positive patients with low CD4 counts, which may result in development of fatal complicated infection. In HIV, an association with lower CD4 counts indicates the need for inclusion of Strongyloides as an opportunistic parasite<sup>2</sup>.

Stool of an alcoholic patient was also found to be positive for occult blood & Rhabditiform larva of *Strongyloides stercoralis*. Alcoholism should be considered a risk factor for Strongyloidosis<sup>2</sup>. All 3 cases responded well with Albendazole & Ivermectin.

Early diagnosis of Strongyloidosis is a real challenge. Therefore, a high index of suspicion is required to start appropriate therapy in immunocompromised patients with high eosinophil count and in high-risk patients to reduce high mortality rate.

## CONCLUSION

The best approach for the prevention & control of *Strongyloides stercoralis* is by improvement in sanitation. Awareness of the possibility of systemic Strongyloidosis is essential during immunosuppressive therapy with high eosinophil count and in high-risk patients. Screening using serology (ELISA) should be done in patients who are on immunosuppressive medications, currently or previously living in endemic countries. Positive cases should be followed by repeated examination of several stool specimens collected on different days<sup>5</sup>. Early detection can prevent most of the fatal infections caused by *Strongyloides stercoralis*.

Albendazole is effective with minimal side effects. However, Ivermectin is considered to be the gold stan-

dard recommended therapy for Strongyloidiasis. Repeated cycles of therapy lasting at least 7 to 14 days have to be considered in immunosuppressed patients. The duration of the treatment & optimal dosage is however not clearly defined in case of hyperinfection syndrome<sup>1,5</sup>.

## REFERENCES

1. Andreas Sing, Lorenz Leitritz, Johannes R. Bogner, et al. First-Glance Diagnosis of *Strongyloides stercoralis* Autoinfection by Stool Microscopy. J Clin Microbiol 1999 ; 37 (5); 1610-1611.
2. Chordia P, Christopher S, Abraham O C et al. Risk factors for acquiring *Strongyloides stercoralis* infection among patients attending a tertiary hospital in south India. Indian J Med Microbiol 2011; 29 (2):147-151
3. Marcos LA, Terashima A, Dupont HL et al. Strongyloides hyperinfection syndrome: An emerging global infectious disease. Trans R Soc Trop Med Hyg 2008; 102: 314-8.
4. Lam CS, Tong MK, Chan KM et al. Disseminated strongyloidiasis: A retrospective study of clinical course and outcome. Eur J Clin Microbiol Infect Dis 2006; 25: 14-8.
5. Stephen H. Gillespie Richard D Pearson. Principles and Practice of Clinical Parasitology, West sussex, England, John Wiley & Sons Ltd, 2001 , 479-500.
6. Google images [http:// eso-cdn.bestpractice.bmj.com/bestpractice/images/bp/er](http://eso-cdn.bestpractice.bmj.com/bestpractice/images/bp/er)