

CASE REPORT**ACUTE DISSEMINATED ENCEPHALOMYELITIS IN CHICKEN POX**Arijit Sinha¹, Suvrendu Sankar Kar², Tirtha Pratim Purkait¹, Uttam Kumar Pandit³**Author's Affiliations:** ¹Assistant Professor; ³Resident, Department of Medicine, Infectious Disease Hospital; Assistant Professor, Department of Medicine, R.G.Kar Medical College, Kolkata**Correspondence:** Dr Suvrendu Sankar Kar Email: dr_sskar@yahoo.co.in**ABSTRACT**

An 11 years old male was admitted with upper motor type of weakness of both lower limbs, retention of urine, impaired consciousness, tremor and convulsion on 11th day after vesicular eruption of chickenpox. He was investigated and treated. MRI Brain and Spine suggests encephalitis and myelitis. Other causes were excluded by relevant investigations. Patient was improved satisfactorily.

Key words: Chickenpox, Acute Disseminated Encephalomyelitis**BACKGROUND**

Chickenpox or varicella is a contagious disease caused by varicella zoster virus. Infections are usually self limiting but complications may occur like pneumonia, encephalitis or secondary pyogenic skin infection etc. CNS complications rate varies from 0.1 to 0.7% in several series¹ Acute disseminated encephalomyelitis (ADEM) is one of the rare CNS complications of chicken pox. ADEM is a demyelinating disease of the CNS which can occur following viral infections like chicken pox, measles, rubella, mumps, influenza, Epstein Barr virus, HIV and mycoplasma; following vaccination or spontaneously. Classically ADEM is a monophasic disease but it may have a recurring course also.² It is associated with small foci of scattered, perivenular inflammation and demyelination of brain and spinal cord.³ In our case, the patient was admitted at Infectious Disease Hospital, Kolkata on 11th day of illness.

CASE REPORT

An 11 year male patient was suffering from Chickenpox and treated at home without antiviral drugs. On 11th day he noticed sudden weakness of both lower limbs with band sensation at nipple level of the chest and retention of urine. Gradually his consciousness level became impaired, tremor of upper limbs and convulsion developed. He was of average built with normal birth and developmental milestones, not immunized against chickenpox, no history of recent vaccination and no significant past illness.

Examination: Patient had impaired consciousness (GCS 4); blood pressure (100/70), heart rate (88/min) was normal. He was not pale and clubbing, lymphadenopathy, icterous, oedema, fever were ab-

sent. His respiratory, cardiovascular, abdominal findings were within normal limits.

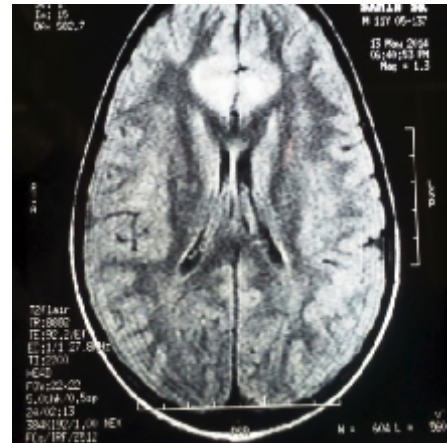


Figure 1: Hyperintensities on T2 image involving bilateral parafalcine region of both frontal lobes with mild surrounding oedema (suggestive of encephalitis)

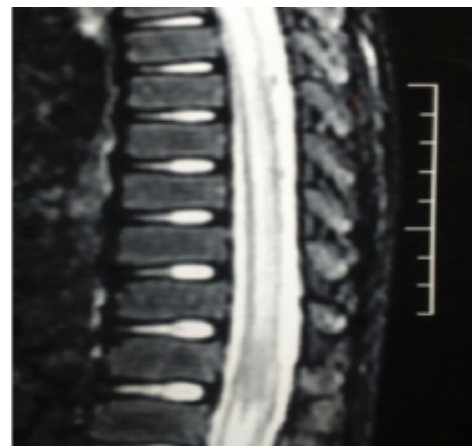


Figure 2: MRI (T2 image) of cervico-dorsal spinal cord showing long segment intramedullary hyperintensities (long segment myelitis)

Positive findings on examination of nervous system were—impaired consciousness, lateral gaze nystagmus, tremor, loss of muscle power, flaccidity, loss of abdominal reflex, extensor planter response and diminished sensation below D4 dermatome.

Investigations: Patients investigation reports were as follows : Haemoglobin 10.6 gm/dl, leucocyte count 6400/cumm (N58, L40, E2), ESR 50 mm, total bilirubin 0.98 mg%, SGPT 46 IU /L, urea 36mg/dl, creatinine 0.8 mg /dl, Na 136 Meq/L, K 4.8 Meq/L, PO4 3.8 Meq/L, Mg 1.5 Meq/L, Ca 10.8 Meq/L, HIV1 & 2 negative, ANF negative, antiphospholipid antibody negative, IgM VZV positive in 1: 128 dilution, CSF cellcount 56/cumm with 90% lymphocytes, sugar 40 mg/dl, protein 68mg/dl, ADA 4 IU/L, no oligoclonal band. Chest X ray normal and ECG were normal. MRI Brain and Spine revealed abnormal T2 hyperintensities involving bilateral parafalcine region of both frontal lobes with mild surrounding oedema, suggestive of encephalitis (Figure 1) and abnormal intramedullary long segment T2 hyperintensities involving the cervico-dorsal spinal cord suggestive of long segment myelitis (Figure 2).

Treatment and course: Patient was treated with injectable Acyclovir and methylprednisolone, phenytoin and other supportive management. He was improved satisfactorily and discharged on 7th day of hospital admission with mild weakness of lower limbs and mild dysarthria. On follow up after one month he was fine, without any neurodeficit.

DISCUSSION

Encephalitis, cerebellitis, meningitis, optic neuritis, G B Syndrome, transverse myelitis, stroke, mono or polyneuritis are common CNS complication of chickenpox. ADEM is a rare but serious complication of chickenpox. Children are most sufferers.^{4,5} Association of ADEM following chickenpox may be delayed up to two weeks.⁶ In our case age of the patient was 11 years and complication started on 11th day after appearance of rash. ADEM following chickenpox is abrupt in onset with rapid progression, usually when exanthema is fading. Fever, headache, meningismus, seizure, ataxia, tremor, nystagmus, impaired consciousness are the usual presentation. There may be features of hemiparesis, paraparesis, quadriparesis, cerebellitis, extensor planter, loss or increased tendon reflexes, sensory loss or brain stem involvement. CSF shows lymphocytic pleocytosis with elevated protein, transient oligoclonal band.⁷ CT scan Brain may be normal. Clinical signs of cerebellar involvement may be normal in MRI. In ADEM there are extensive changes in brain and spinal cord, white matter hyperintense signal in T2, FLAIR sequence with

gadolinium enhancement on T1 weighted sequences.⁸

Treatment of ADEM is supportive and use of high dose of methyl prednisolone with tapering is beneficial. Plasma exchange and intravenous immunoglobulin may be used in steroid non responder cases. Role of methyl prednisolone is established but of acyclovir is controversial.⁹

In our case, patient's onset was acute and presented with features of encephalitis, cerebellitis and myelitis with rapid recovery on methyl prednisolone treatment. Follow up at one month was uneventful.

CONCLUSION

We present a case report on a 11-year old boy who presented with neurological complications on 11th day following the appearance of rash of chicken pox. He was diagnosed as acute disseminated encephalomyelitis and was managed successfully with antiviral and steroid.

Acknowledgment: I would like to acknowledge the patient, his parents and record keeping staff of ID & BG Hospital.

REFERENCES

- Güçüyener K, Kula S, Serdaroglu A et al. Acute disseminated encephalomyelitis exacerbated by varicella. *Acta Paediatr Jpn.* 1997 Oct;39(5):619-23.
- Marchioni E, Ravaglia S, Piccolo G et al. Postinfectious inflammatory disorders: subgroups based on prospective follow-up. *Neurology.* 2005 Oct 11;65(7):1057-65.
- Alvord BC Jr: Demyelinating disease, In Vinken PJ, Bruyn GW eds *Handbook of Clinical Neurology*, Elsevier Publisher BV, Amsterdam, 1985,3,467-502
- Whitley J Richard, Varicella-Zoster virus infections, In Harrison's *Principles of Internal Medicine*, 18th edition, vol 1, 1462-66
- Miller HG, Stanton JB, Gibbons JL, Para infectious encephalomyelitis and related syndromes, a critical review of neurological complication of certain specific fevers, *Q J Med*, 1956,25(100),427-505
- LaRovere KL, Raju GP, Gorman MP, Post varicella acute transverse myelitis in a previously vaccinated child, *Pediatric Neurol*, 2008,38(5),370-72
- deSeze J, Debouverie M, Zephir H et al, Acute fulminant demyelinating disease: a descriptive study of 60 patients, *Arch Neurol* 2007,64(10),1426-32
- Hynson JL, Kornberg AL, Coleman LT et al, Clinical and neurologic features of acute disseminated encephalomyelitis in children, *N Neurology*, 2001,56(10),1308-12
- Saabire G, Hollenberg H, Meyer L, Huault G, Landrieu P, Tardieu M, High dose methyl prednisolone in severe acute myelopathy, *Arch Dis Child*, 1997,76(2)167-68