

## Original Article

# Evaluation of Results of Multiplanar Fixation in Lower Third Tibia Fracture

Sanjay N Modi<sup>1</sup>, Jigneshkumar L Baria<sup>2</sup>

**Authors' affiliation:** Associate Professor, Dept. of Orthopaedic, SMIMER, Surat; Sr. Resident, Dept. of Orthopaedic, BJMC, Ahmedabad

**Correspondence:** Dr. Sanjay Modi, Email: modisn@hotmail.com, Mobile No.:9825184484

## ABSTRACT

**Introduction:** The objective to assess and analyze the Functional, Radiological and Clinical outcomes of operatively managed lower third tibia fractures using distal tip interlock nail.

**Methods:** With the ethical committee approval from the SMIMER medical college, Surat the descriptive longitudinal study was done on 25 patients. Patients who sustained extrarticular distal tibia fractures from 4cms - 11cms above the tibial plafond and were treated by intramedullary interlocking nailing were included in the study. Both open and closed fractures were included. Patients with pathological fractures, stress fractures, paediatric patients (< 14 years of age), metabolic bone diseases, distal tibia fractures with intra-articular involvement.

**Results:** The average time taken to partial weight bearing was 8.16 weeks (range of 4 weeks to 12 weeks). The average time taken to full weight bearing was 13.2 weeks (range of 10 weeks to 18 weeks). The average time taken to return to work was 29.68 weeks (range of 12 weeks to 54 weeks).

**Conclusion:** Distal tibia metadiaphyseal fractures may be treated successfully with low, multidirectional locked nails. Low, multidirectional locked nailing may represent a superior surgical option, since it offers advantages in terms of mean operating time, hospital stay, full weight-bearing time and union time involvement.

**Key words:** Multiplanar fixation, tibia fracture

## INTRODUCTION

The rapid growth of technology and urbanization has led to enormous growth of new vehicles on road. This has led to increase in road traffic injuries and deaths. Globally the number of deaths in major road traffic accidents is estimated at 1.2million deaths /year while the number injured is as high as 50 million injuries /yr. Without increased efforts to prevent these injuries the number of Road traffic deaths worldwide is projected to increase 65% between 2000 and 2020. In under developed and developing countries these deaths are expected to increase by as high as 80 %.<sup>1</sup>

In India, more than 1, 00,000 lives are lost due to road traffic accidents every year (WHO global safety report 2011)<sup>2</sup>. According to WHO Report in 2002 road traffic injuries were ranked as the ninth cause of death in all and ranked as fourth cause of death in 2008. In India it is ranked as 6<sup>th</sup> leading cause of death. A 4.4 fold increase has been detected in the number of road traffic accidents between the years 1970- 2011. Subsequently the number of deaths has increased by 9.8 folds and the number of injuries by 7.3 folds. To note is that one third of fatalities in India involve the pedestrians and two wheelers who are called as the 'vulnerable road users'. Under developed and developing countries account for 91.8% of DALY's lost to road traffic injuries worldwide.

The injury due to these accidents commonly involve the long bones especially tibia due to its subcutaneous location. On the basis of location, distal tibia fractures are

second in incidence next to tibia diaphyseal fractures<sup>3</sup>. The distal tibia due to its subcutaneous blood supply and tenuous blood supply pose a challenge to treating surgeons in terms of choosing an appropriate implant to achieve adequate union and return to early pre injury levels.

## OBJECTIVES

The aim of the study to evaluation of results of multiplanar fixation in lower third tibia fracture. The objective to assess and analyze the Functional, Radiological and Clinical outcomes of operatively managed lower third tibia fractures using distal tip interlock nail.

## METHODS

With the ethical committee approval from the SMIMER medical college, Surat the descriptive longitudinal study was done on 25 patients. Patients who sustained extrarticular distal tibia fractures from 4cms – 11cms above the tibial plafond and were treated by intramedullary interlocking nailing were included in the study. Both open and closed fractures were included. Patients with pathological fractures, stress fractures, paediatric patients (< 14 years of age), metabolic bone diseases, distal tibia fractures with intra-articular involvement.

The functional outcome was calculated using a standard set of questions. We used the AOFAS score. The Ameri-

can orthopaedic Foot and Ankle Society Score (AOFAS) introduced Kitaoka et al in 1994.<sup>4</sup>

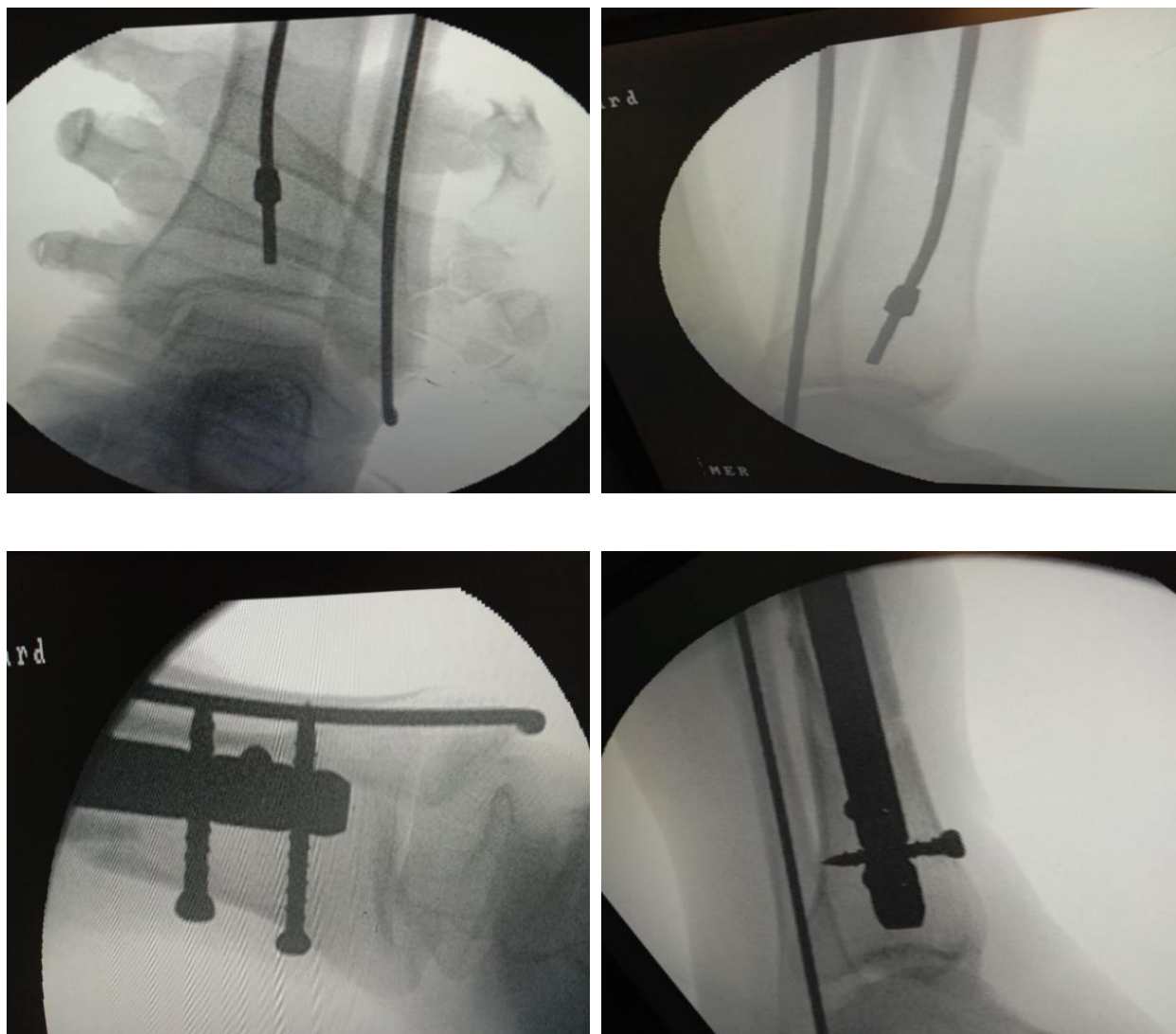
Radiographic assessment included mal-alignment, time to union and loss of reduction. Radiographic assessment was done comparing the anteroposterior and lateral views of the affected leg with both the knee and ankle joints included. The varus/valgus angles were calculated by the Paley and Tetsworthmethod.<sup>5</sup> Lines were drawn horizontally over the tibial plateau and tibial plafond. Their midpoints were identified and connected with a vertical line. Then a perpendicular was drawn to the horizontal line over the tibial plafond. The angle formed between the perpendicular and line joining the midpoints of the plateau and plafond was considered as the varus/valgus angle based on lateral or medial angulation respectively. The same method was followed in the lateral view to calculate the procurvatum/recurvatum angles. These angles were calculated from the immediate postoperative radiograph and the final followup radiograph. The residual deformity, mal alignment and loss of reduction were noted.

It was ensured that adequate flexion of the knee was possible to achieve central placement of the guide wire with-

out hitting the posterior cortex. Concurrent fibula fixation was done in 9 cases. The decision to fix fibula before tibia nailing or after nailing was under the sole discretion of the operating surgeon. Fibula fixation was done either to achieve alignment of the fracture, achieve length or to increase stability. When fibula was decided to be fixed first, fibula fracture was exposed through a lateral incision.

Fracture was reduced and fixed with RUSH NAIL or 1/3<sup>rd</sup> tubular plates, after which the limb was held by the side of the table and the tibial nailing was done. A 5cm skin incision was made from tip of tibial tuberosity extending proximally to the lower pole of patella. The patellar tendon splitting approach was used in all cases. The entry point was made with an awl just below the articular margin of the tibial plateau in lateral view and medial to the lateral tibial spine in antero posterior view after confirming there was no rotational mal alignment of tibia with an image intensifier. Guide wire was passed and fracture reduction was achieved manually.

Implants used: Distal Tip tibia interlock Nail with two proximal interlocks and two distal medial lateral locks and 1 antero posterior locks.



**Figure 1 – Central placement of guide wire & nailing with three distal locking screws placed**

The patients were followed up at 4-6 weeks for upto 6-12 months to assess clinical and radiological union. After the 1-2 follow up of 4-6 weeks patient is allowed to bear partial weight with help of walker. This walker is allowed for 4 weeks and later removed and patient is allowed to full weight bear walk.

Clinical union was considered when there was no pain at fracture site on palpation and patient was able to stand and walk weight bearing on the affected lower limb. The fracture was designated as radiologically united, when there was periosteal bridging callus at the fracture site at least in three cortices in antero-posterior and lateral views. Trabeculations extending across the fracture site was also taken into consideration. Partial and full weight bearing were allowed based on the radiological union and consolidation of the fractures and signs of clinical union.

## RESULTS

25 Patients who were followed up were included in the study for evaluation of multiplanar fixation for their distal tibia extrarticular fractures. Out of the 25 patients there were 19 males and 6 female patients. The mean age of the patients at the time of injury is 37.12 years (range of 17 to 72 years). The minimum follow up period was 12 months and maximum of upto 24months. Mechanism of injury was of high energy in 21 patients (84%) and low energy in 4 (16%). Out of 25 patients, 15 (60%) had sustained closed fractures and 10 (40%) patients have sustained open fractures. The average time taken to do surgery was 5.58 days (range of 1 day to 15 days). Concurrent fibula fixation was done in 9 cases. Fibula fixation was done with either Rush Nail or 1/3 Tubular plates

### Radiological characteristics:

The average distance of fracture site from the tibial plafond was 8.26cms (range of 4cm to 10.8cms). It was observed that the fracture site of 9 patients who had valgus mal-alignment was on an average 8cm from the tibial plafond. The average time taken to radiological union was 20.04 weeks (range of 12 weeks to 34 weeks). The radiological parameters revealed that none of the patients had a varus mal alignment in the immediate post op X-ray. The average valgus angle in the immediate post op period was 5.35 degrees (Range of 0 degree to 13.2 degrees). 12 patients had a valgus angle more than 5 degrees. The final follow up X-rays showed 9 patients with valgus angle more than 5 degrees. Out of 9 patients, 5 patients had higher valgus than the immediate post op period indicating a loss of reduction and malunion. The average valgus angle in final follow up period is 4.36 degrees (Range of 0 to 14.8). The measurement of radiological parameters in the lateral view in the immediate post op period revealed that 2 patients had procurvatum/recurvatum angle more than 10 degrees. The average procurvatum/recurvatum angle was 5.24 degrees (Range of 0 to 14 degrees). The final follow up X-rays revealed 4 patients with more than 10 degrees of procurvatum/recurvatum angle. All four had higher procurvatum/recurvatum angles than the immediate post op period indicating a loss of reduction or mal-alignment. The average procurvatum/recurvatum angle in the final followup x-rays were 4.56 degrees (Range of 0 to 16.5 degrees). Nine patients had final follow up radiological parameters suggesting of malunion as per the

diagnostic criteria. (Valgus/Varus angle more than 5 degrees in AP view, Procurvatum / Recurvatum angle more than 10 degrees in lateral view).

The average time taken to partial weight bearing was 8.16 weeks (range of 4 weeks to 12 weeks). The average time taken to full weight bearing was 13.2 weeks (range of 10 weeks to 18 weeks). The average time taken to return to work was 29.68 weeks (range of 12 weeks to 54 weeks).

### Complications

In the followup examination where the minimal followup period was 12 months and maximum followup of upto 24 months with a mean of 18 months, wound healing was 96%. Out of 25 patients, 2 patients had fracture site tenderness, pain on full weight bearing and radiological union of only two cortices out of 4. Those 2 patients were considered as non-union. 4 patients underwent additional procedures. Mostly for their soft tissue cover in the form of split thickness skin grafting & dynamisation except for one patient in whom external fixator was done previously and after external fixator removal nailing done.

The correlation between the variables measured and the scores were analysed using sample T-Test. There was significant correlation between both the functional scores with sex of the patient. It was observed that female patients performed poorly compared to male patients. The other variables like time to return to work and degree of alignment did not correlate significantly with the scores which is given in the table below.

The sample T-test was also used to identify associations between other possible predictive variables like fibula fixation and radiological union with post-operative varus/valgus malunion. The analyses showed no significant correlation between the variables which is shown in the table below.

Significant correlation was found between valgus malunion and radiological union. Patients with high valgus mal-alignment i.e. more than the acceptable criteria of 5 degrees are prone for delayed radiological union than patients with acceptable limits of mal-alignment.

It was observed that valgus mal alignment was found more frequently in patients with more lateral comminution. Similarly patients with more posterior comminution presented with procurvatum deformity. To note one patient with anterior comminution developed a recurvatum deformity.

## DISCUSSION

Advantages of intramedullary nailing compared to other forms of fixation like plating and external fixation in tibial fractures alone cannot support the use of intramedullary nailing in distal tibial fractures of tibia. The problems of extending the indication to use in extrarticular metaphyseal fractures of tibia should be analysed and addressed for coming out with excellent functional outcomes.

Van derschoot<sup>6</sup> study of 88 patients with 15 years follow up also revealed that more arthritis was found in the ankle joint adjacent to the fracture than compared to the ankle in uninjured limb. Puno et al<sup>7</sup> observations also con-

firmed that poorer clinical results are associated with mal-aligned fractures of tibia.

Kyro in his article of 64 tibial shaft fractures concluded that malunion of tibial shaft fractures seems to produce more complications in distal tibia fractures, in fractures with marked previous displacement, in fractures caused by high energy injury and in patients age > 45 yrs.

The functional outcomes assessed, when analysed, revealed the fact that worse functional outcomes were not related with age or associated injuries. It was associated with the quality of reduction of the fracture. The significant clinical correlation of radiological union with valgus mal-alignment in our study proves this fact. The mean time to radiological union after IM nailing for distal tibia fractures was in a range 17.7-22.6 weeks.<sup>8</sup> The mean time to radiological union in our study is 20.04 weeks. This is well within the range recommended in the literature. The radiological union of fractures of patients with more valgus mal-alignment were comparatively delayed. This explains the need for perfect alignment of fracture intraoperatively to achieve better functional outcomes. This perfect alignment can be achieved by several means. The increased rate of mal-alignment thus can be controlled.

The overall patient satisfaction is always related to improved physical function and ability to return to work. This applies to population all over the world. In Indian population particularly patients and their dependants are more eager to know on their time to return to job or functional normality than knowing the type of treatment they are going to receive. In this context our study has showed a mean time to return to work as 29.68 weeks (4.24 months). This is comparatively less time when considering both open and closed tibial fractures. Literature<sup>9</sup> has given an average of 5months' time to return to work of patients who underwent nailing for distal tibia fractures. It has also been reported that nearly 95 % of patients have returned to their work post distal tibia fractures no matter what the type of fixation was.<sup>10</sup> Out of which 70 % had returned to moderate to heavy jobs which they were previously performing before the injury.<sup>11</sup> Our study has shown that nearly 91.6% of patients had returned to work (22 out of 24), 62.5% of patients had returned to their previous jobs and 37.5% had changed their jobs post injury.

The AOFAS score has performed well in estimating the functional outcome in our study. Women performed poor and had low scores compared to men. This was comparable to be Valliers study in 2011<sup>11</sup> where functional scores of women were poor.

The rate of non-union in IM nailing of distal tibia fractures is 5.5 % . Two patients had nonunion in our study (8.0%). The fracture was well aligned within acceptable limits during immediate postop. There was no evidence of any infection. The patient's ankle scores were fair. The incidence of infection in our study was 4%. This explains the advantage of IM nailing over plating in distal tibia by open reduction or MIPO. The rate of incidence of infection in literature in IM nailing is 4.3%<sup>12</sup>

There was no statistical correlation between fibula fixation and radiological union. Out of 9 patients in whom fibula was fixed nearly 3 had post op valgus mal alignment.

It also showed that alignment should be carefully checked during the procedure to reduce the rate of mal-alignment. The sample size is low to achieve statistically significant correlations. Secondly the patients were followed upto 12 months post op. Third, the preoperative X-rays and immediate post op X-ray were not adequately showing the proximal knee joint for mal-alignment angle measurement. In such case we used the midpoint of the shaft as reference for upper end and midpoint of plafond as reference for lower end.

## CONCLUSION

Distal tibia metadiaphyseal fractures may be treated successfully with low, multidirectional locked nails. Low, multidirectional locked nailing may represent a superior surgical option, since it offers advantages in terms of mean operating time, hospital stay, full weight-bearing time and union time.

## REFERENCES

1. Dhillon MS, Rajasekharan S, Sancheti P. Status of Road Safety and Injury Burden: India. *J Orthop Trauma*. 2014 Jun;28:S43-4.
2. WHD4•RepCovEn\_CAG - intro.pdf.
3. Court-Brown CM, Caesar B. Epidemiology of adult fractures: A review. *Injury*. 2006 Aug;37(8):691-7.
4. Strauss EJ, Alfonso D, Kummer FJ, Egol KA, Tejwani NC. The effect of concurrent fibular fracture on the fixation of distal tibia fractures: a laboratory comparison of intramedullary nails with locked plates. *J Orthop Trauma*. 2007 Mar;21(3):172-7.
5. Morin PM, Reindl R, Harvey EJ, Beckman L, Steffen T. Fibular fixation as an adjuvant to tibial intramedullary nailing in the treatment of combined distal third tibia and fibula fractures: a biomechanical investigation. *Can J Surg*. 2008 Feb;51(1):45-50.
6. Van der Schoot DK, Den Outer AJ, Bode PJ, Obermann WR, van Vugt AB. Degenerative changes at the knee and ankle related to malunion of tibial fractures. 15-year follow-up of 88 patients. *J Bone Joint Surg Br*. 1996 Sep;78(5):722-5.
7. Puno RM, Vaughan JJ, Stetten ML, Johnson JR. Long-Term Effects of Tibial Angular Malunion on the Knee and Ankle Joints. *J Orthop Trauma*. 1991 Sep;5(3):247-54.
8. Xue X-H, Yan S-G, Cai X-Z, Shi M-M, Lin T. Intramedullary nailing versus plating for extra-articular distal tibial metaphyseal fracture: a systematic review and meta-analysis. *Injury*. 2014 Apr;45(4):667-76.
9. Dogra AS, Ruiz AL, Thompson NS, Nolan PC. Dia-metaphyseal distal tibial fractures--treatment with a shortened intramedullary nail: a review of 15 cases. *Injury*. 2000 Dec;31(10):799-804.
10. S.T.Canale. *Campbells operative orthopaedics*. 10th ed. Elsevier; 2003
11. Vallier HA, Le TT, Bedi A. Radiographic and Clinical Comparisons of Distal Tibia Shaft Fractures (4 to 11 cm Proximal to the Plafond): Plating Versus Intramedullary Nailing. *J Orthop Trauma*. 2008 May;22(5):307-11.
12. Zelle BA, Bhandari M, Espiritu M, Koval KJ, Zlowodzki M, Evidence-Based Orthopaedic Trauma Working Group. Treatment of distal tibia fractures without articular involvement: a systematic review of 1125 fractures. *J Orthop Trauma*. 2006 Jan;20(1):76-9.