

CASE REPORT

Case of Acute Postpartum Infective Sacroiliitis

Santosh S Borkar¹, Shivraj S Konde², Sidheshwar S Thosar³, Siddharth Kumar³

Authors' affiliations: ¹Professor; ²Asso. ²Prof; ³Resident, Dept. of Orthopaedic, MIMER, Talegao, Pune

Correspondence: Dr. Shivraj S Konde, Email: drshivraj.konde@gmail.com

ABSTRACT

We report a case of unilateral postpartum infective sacroiliitis. Patient 24 year old female, presented with severe unilateral lumbogluteal pain few days after LSCS with leucocytosis, elevated erythrocyte sedimentation rate, C Reactive protein and confirmed radiologically by x-ray pelvis with both hip joint and MRI scan. Diagnosis was supported by onset after delivery, clinical, biological and radiological findings and favourable evolution under antibiotic therapy.

Keywords: Sacroiliitis, infective, Postpartum, lumbogluteal.

INTRODUCTION

Sacroiliac strain, septic sacroiliitis and inflammatory sacroiliitis without sepsis are described in literature in post partum period¹. There is greater demand on sacroiliac joint in pregnant women due to weight gain and hormonal changes and sacroiliac strain is not uncommon¹. However sacroiliitis either septic or inflammatory is relatively less common. During pregnancy infection appears to be bilateral in 13.3 % of cases¹. Infectious sacroiliitis is rare and constitutes only 1 to 2 percent of septic arthritis cases due to poor vascularisation of this joint resulting in low risk of infection via the hematogenous route². Patients present with lumbogluteal pain and occasionally fever. Risk factors for infectious sacroiliitis are pelvic trauma, infectious endocervicitis, hemoglobinopathy, immunosuppressive treatment, URTI or genitourinary infections etc³. Differential diagnosis could be spondyloarthropathy usually rarely prolapsed intervertebral disc, spondylodiscitis etc.⁴ Hence we decided to report this rare case of postpartum infective sacroiliitis.

CASE REPORT

A 22 year female underwent lower segment caesarean section for primigravida foetal distress, Postoperatively, after 2-3 days patient developed unilateral (right) sided intense pain even at rest in bed which was aggravated by even slight movement in bed or touching of that region. Pain was aggravated by pelvic compression test, Ganslen's test and pump handle test. There was localized tenderness over right sacroiliac joint. Patients ESR was 40 mm/hr. Total leucocyte count was 11200/cumm (raised).

CRP was positive (192 mg/dl). RA factor and HLAB 27 was negative. There was mild elevation of alkaline phosphatase. Radiograph of pelvis were suggestive of infection in the right sacroiliac joint.

MRI Scan of sacroiliac joint with screening of right hip joint showed extensive right sacroiliitis with small collection on the inferior aspect of the joint which was suspicious of infective etiology. MRI scan said that inflammatory arthropathy was less likely. Screening of hip joints and spine was unremarkable.

Aspiration of sacroiliac joint under fluoroscopic control was done which yielded only a few drops of fluid. Fluid was sent for culture and sensitivity which yielded no organism. Gram stain and ZN stain for AFB also did not yield any organism. However high vaginal swab which was taken yielded MRSA.

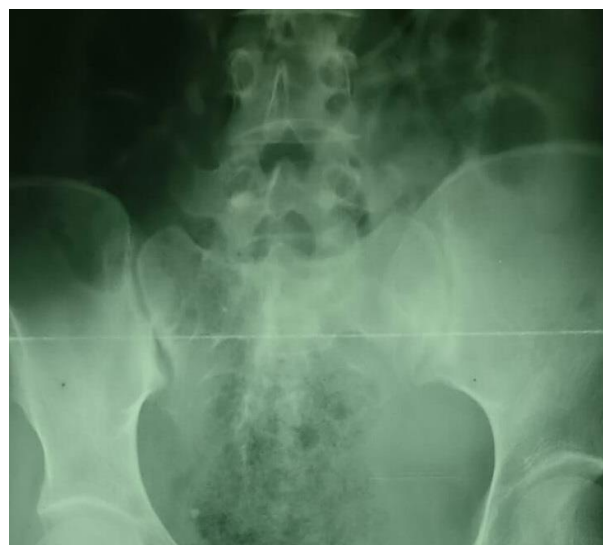


Figure 1: X-ray showing sacroiliitis

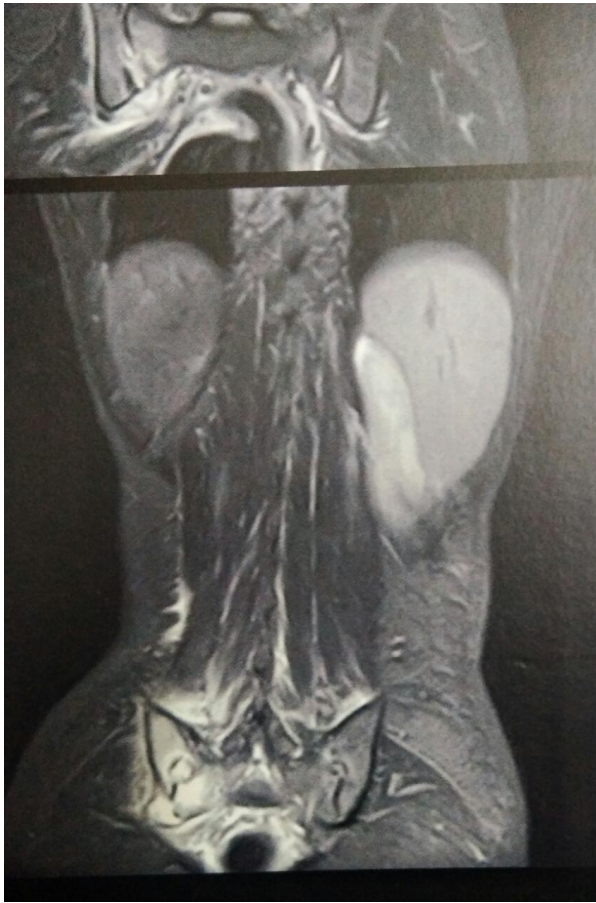

Figure 2- MRI picture of sacroiliitis

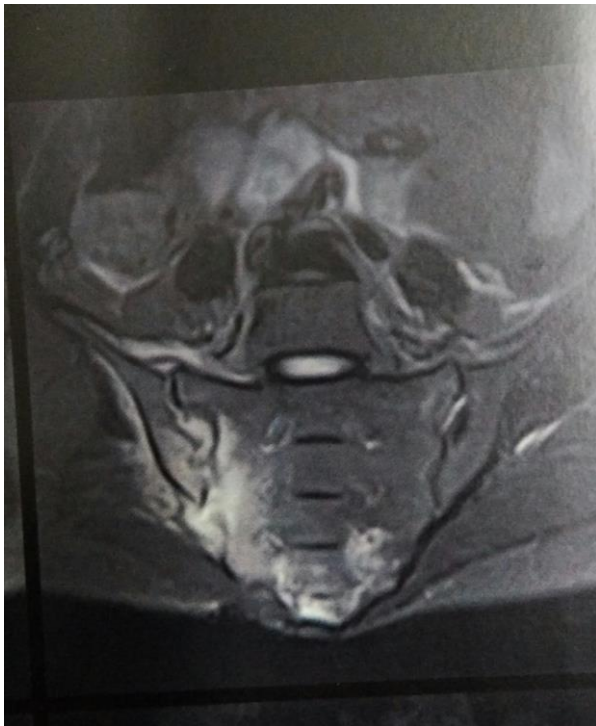

Figure 3- MRI picture of sacroiliitis

Hence there was septic focus detected. However sacroiliac joint did not yield any organism. Hence we decided to treat this case as a case of infectious sa-

croiliitis and started patient on injection Ceftriaxone 1 gm iv 12 hrly and Gentamicin 80mg / kg iv eight hourly.

Along with antibiotics, Inj paracetamol 1 gm iv TDS with oral Indomethacin 25 mg TDS was given . After two weeks of antibiotic treatment, patient was shifted to oral antibiotics and discharged. Follow up x-ray at one month showed no erosive changes . Patient recovered almost totally at six weeks.

DISCUSSION

Pain in sacroiliac joint in the postpartum period has been described before. In last trimester of pregnancy hormonal changes cause sacroiliac joints to relax and there is softening of ligaments for preparing pelvis for passage of foetus through pelvic outlet. Earlier researches like Trousseau described this condition as sacroiliac strain as most often fever is absent.⁵ Young gave the name sacroiliac arthropathy to this condition.⁶ However differential diagnosis of this condition is pyogenic sacroiliitis but is associated with systemic signs of infection. Radiographic changes are often seen in this condition including joint erosion, sclerosis of adjoining bone etc.⁷ Pyrexia, leucocytosis and raised ESR with detection of an infectious focus (urinary tract, vagina, uterus etc) should raise suspicion of infectious sacroiliitis. However many researchers like Gaucher et al question whether this condition is indeed infectious as often organism is not found on aspiration of sacroiliac joint as in our case.⁸ We did not get any RA factor HLA B27 positive result to treat it as spondyloarthropathy.⁹ Hence we treated it on the lines of infectious sacroiliitis and got good result and follow up. In our case sacroiliitis was only unilateral and not bilateral as is reported in literature many cases in the postpartum period.¹⁰ Also we had ruled out tuberculosis and brucellosis as causative agent for this type of infectious sacroiliitis.¹⁰ Diagnosis was supported by onset after delivery , clinical, biological and radiological findings and favourable evolution under antibiotic therapy.

Declaration of patient consent-

The authors certify that they have obtained all appropriate patient consent forms which includes her consent for images and other clinical information with due efforts to conceal their identity

REFERENCES

1. Linnet, Karen M., Lise Gammelgaard, Mona Johansen, Niels Krarup, and Kjeld L. Rasmussen. "Bilateral pyogenic sacroiliitis following uncomplicated pregnancy and labor." *Acta obstetrica et gynecologica Scandinavica* 75, no. 10 (1996): 950-951.
2. Floman YI, Milgrom CH, Gomori JM, Kenan SH, Ezra YO, Liebergall ME. Acute postpartum inflammatory sacroiliitis. A

- report of four cases. *The Journal of bone and joint surgery. British volume.* 1994 Nov;76(6):887-90.
3. Mavian Hermet M, Minichiello E, Flipo RM, Dubost JJ, Allanore Y, Ziza JM, Gaudin P, Thomas T, Dernis E, Glace B, Regnier A. Infectious sacroiliitis: a retrospective, multicentre study of 39 adults. *BMC infectious diseases.* 2012 Dec;12(1):305.
 4. Wilbur, Andrew C., Bradley G. Langer, and Dimitrios G. Spigos. "Diagnosis of sacroiliac joint infection in pregnancy by magnetic resonance imaging." *Magnetic resonance imaging* 6, no. 3 (1988): 341-343.
 5. Trousseau A Sur le relacement symphyses du bassin clin med 1873;4;810-8
 6. Young, James. "Relaxation of the pelvic joints in pregnancy: pelvic arthropathy of pregnancy." *BJOG: An International Journal of Obstetrics & Gynaecology* 47.5 (1940): 493-524.
 7. Resnik, Charles S., and Donald Resnick. "Radiology of disorders of the sacroiliac joints." *Jama* 253, no. 19 (1985): 2863-2866.
 8. Gaucher, Alain, et al. "Autosomal dominant arthropathy in a french family." *Arthritis & Rheumatism: Official Journal of the American College of Rheumatology* 34.6 (1991): 737-743.
 9. Godfrin, Bertrand, et al. "Spondyloarthropathy with enthesal pain. A prospective study in 33 patients." *Joint Bone Spine* 71.6 (2004): 557-562.
 10. Delbarre, F., et al. "Pyogenic infection of the sacro-iliac joint. Report of thirteen cases." *The Journal of bone and joint surgery. American volume* 57.6 (1975): 819-825.