

ORIGINAL ARTICLE

FINE NEEDLE ASPIRATION CYTOLOGY AS A FIRST LINE INVESTIGATION IN THYROID LESIONS

Mandakini M Patel¹, Komal Patel², Kumarbhargav R Kaptan³, Sonal L Italiya³, Gurvindersingh Saini⁴**Authors' Affiliation:** ¹Additional Professor, ²Assistant professor, ³Senior resident, ⁴Junior resident Department of Pathology, Government Medical College, Surat, Gujarat, India**Correspondence:** Dr. Mandakini M. Patel, E-mail: mandakini7009@gmail.com

ABSTRACT

Introduction: Fine needle aspiration cytology (FNAC) is regarded as the gold standard investigation in diagnosis of thyroid swellings especially to rule out need of surgery.**Aims:** To study role of FNAC in thyroid lesions.**Materials and Methods :** During period of 1 year from 1st January to 31st December 2011 aspiration cytology is been carried out in 194 thyroid swellings referred to cytology department of our institute which is a tertiary care hospital in Surat to study the role of FNA cytology in various thyroid lesions. Fine needle aspiration cytology was performed using mainly non-aspiration and aspiration techniques.**Results:** The cytological samples were assessed by qualified consultant pathologist and were classified as inadequate, non-neoplastic, neoplastic, and indeterminate. Fine needle aspiration cytology analysis revealed 180 (92.78%) non-neoplastic, 10 (5.16%) neoplastic and 4 (2.06%) indeterminate aspirates. 15 (7.73%) samples were inadequate from total of 194 samples.**Conclusion:** The results are comparable with the current published data and demonstrate that FNA cytology in our hands is accurate investigation for further management of thyroid lesions. Also The Bethesda System of Reporting thyroid cytology is vital guide and should be followed to maintain uniformity as a guide to further management.**Keywords:** FNAC, Thyroid lesions, The Bethesda

INTRODUCTION

Fine needle aspiration and cytology (FNAC) is a well-established out-patient procedure used in primary diagnosis of thyroid swellings and assumed dominant role in the management mainly to rule out need of surgery.^{1,2} It has gained acceptance in countries like the UK and USA since 1970s.³ Currently it is practised world-wide and is the investigation of choice in thyroid, breast, and lymph node swellings. The technique has been shown to be simple, safe and cost-effective.⁴ However, the success of FNA is contingent upon several important contributing influences including aspirator experience, skilful interpretation and rational analysis.

MATERIAL AND METHOD

This is a study of 194 cases of thyroid swellings in the Government Medical College, Surat between the periods of January 2011 and December 2011 inclusive. The case notes were retrieved and patients' data regarding history, clinical examination, thyroid function tests, clinical diagnosis, FNAC and histological data

whenever possible were retrieved from the records. The data were analysed in simple statistical tables. The procedures were done by cytopathologist in all the cases. Prior to procedure, a physical examination was carried out to note the mobility of the thyroid during swallowing and the presence of any enlarged cervical lymph node. The patients were made to lie supine with their necks stretched up. A 23-24 gauge needle was used, either without or with aspiration by a 10 ml disposable syringe. Two to three passes were made in each case. The procedure took a fraction of a minute. The aspirated contents of the needle are expelled on to glass slides. In the case of cystic nodules, the cysts' contents were aspirated, centrifuged, and slides made from the sediment for cytological examination. Minimum four slides smear were made, two were air-dried and then fixed and remaining were immediately fixed in 95% ethyl alcohol for about 15 minutes. The slides were stained with MayGrunwald Giemsa (MGG), PAP stain and Haematoxylin and Eosin (H&E) respectively and examined with light microscope. The microscopic diagnosis was interpreted under following categories: - Non neoplastic, Neoplastic and Others. No major complications like penetration into the trachea,

laryngeal nerve palsy, or hematoma were recorded. Only slight pain was reported by some patients. The cytological results were correlated with clinical features, thyroid function tests, and whenever possible by histopathological examination.

RESULTS

Total of 194 cases evaluated by FNAC ranges in age from 6 months to 80 years with maximum cases in 20 – 50 years. The majority of cases were females and female: male ratio was 5.25:1. The major presenting symptom in all the patients was diffuse or nodular swelling of the thyroid with hyperthyroid or hypothyroid features.

Other symptoms were less frequent like pain in the neck region, dysphagia, hoarseness of voice and cough. Patients gave a history of long standing swelling in majority. Thyroid function tests were performed in 74 patients (33.95%) of total 194. Out of which 48 patients (68.87%) were found to be hyperthyroid, 19 patients (25.67 %) hypothyroid and 7 (9.46%) euthyroid. The results were compared with cytological findings. FNAC of 194 patients resulted in the following diagnoses and are shown in Table 1. Diagnoses for 15 cases with FNAC were inadequate because of the lack of cellularity and obscuring factors and diagnosis in such cases were given on the basis of clinical correlation with presence of other factors like abundant colloid like in colloid goitre.

Table 1: Age and gender wise distribution of thyroid lesions (n=194)

Age range	Colloid Goitre	Adenomatous goitre	Thyroiditis	Neoplasia	Cysts	Others*	Total	
							M	F
0-10	5	0	1	0	2	1	3	6
11-20	15	3	12	1	1	0	4	28
21-30	27	6	13	3	1	1	7	44
31-40	33	3	10	1	0	0	6	41
41-50	20	4	7	2	0	1	5	29
51-60	6	2	0	2	0	0	6	4
61-70	4	2	1	1	0	0	0	8
>70	1	0	1	0	0	1	0	3
Total	111	20	45	10	4	4	31	163

M=Male, F=Female; *Others category includes the lesions in which features are not completely fulfilling the criteria of definite diagnosis

Non neoplastic

Colloid goiter: The total of 111 patients were diagnosed to have colloid goiter by FNAC, out of which 17 were males and 94 were females, the female: male ratio being 5.53:1. The average age of these patients was 39.70 ± 15.19 years with a range of 6 months to 80 years. About 45 cases of Colloid goitre evaluated for hormonal status 29 (64.45 %) were found to be hyperthyroid, 11 (24.44 %) were hypothyroid and 5 (11.11 %) were euthyroid.

Adenomatous goiter: Out of 20 patients, 3 were males and 17 were females. The diagnosis was made when the smear showed a profusion of follicular epithelial cells distributed in sheets along with formation of macrofollicles & moderate to scanty amount of colloid. Total 6 out of these 20 cases evaluated for hormonal status, 4 (66.67 %) were hyperthyroid and 2 (33.33%) were hypothyroid. These cases were correlated with clinical diagnosis and radiological findings.

Thyroiditis: In 45 patients, a diagnosis of thyroiditis was made. Lymphocytic and Hashimoto’s thyroiditis were grouped together. 43 of these patients were females and 2 were males with a female to male ratio of 21.5:1. The youngest patient was a 6 year-old female. Total of 21 cases out of 45 cases evaluated for hormonal status, 15 (71.43 %) were hyperthyroid and 6 (28.57 %) were hypothyroid.

Thyroglossal cyst: There were 4 cases of thyroglossal cysts. All were males. Fluid was aspirated and smears

showed scanty cellularity with the presence of squamous cells and macrophages. Youngest case was 6 month year old.

Table 2: Gender wise distribution of all thyroid lesions

	Total Cases	Male	Female
Non-neoplastic	180	26	154
Neoplastic	10	4	6
Others	4	1	3
Total	194	31	163

Table 3: Distribution of non-neoplastic thyroid lesions

	Total	Male	Female
Colloid Goitre	111	17	94
Adenomatous Goitre	20	3	17
Thyroiditis	45	2	43
Benign cysts consistent with thyroglossal cyst	4	4	0
Total	180	26	154

Neoplastic

Out of 14 patients, 4 were males and 6 were females. The diagnosis were papillary carcinoma, Medullary carcinoma, Anaplastic carcinoma and of follicular

neoplasm. Of which anaplastic carcinoma found in older age, papillary carcinoma in around 30 year.

The Others category includes the cases in which features are not completely fulfilling the criteria of definite diagnosis.

DISCUSSION

Thyroid enlargement is a common occurrence in most regions of the world. India has the world's biggest goiter belt in the sub-Himalayan region including the south Gujarat.

Figure 1: Abundant thick colloid in Colloid Goitre.

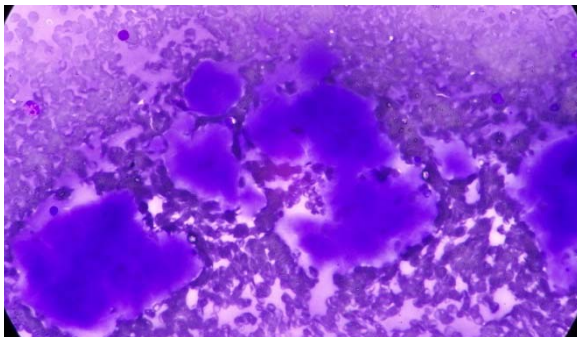


Figure 2: Foamy macrophages in Goitre.

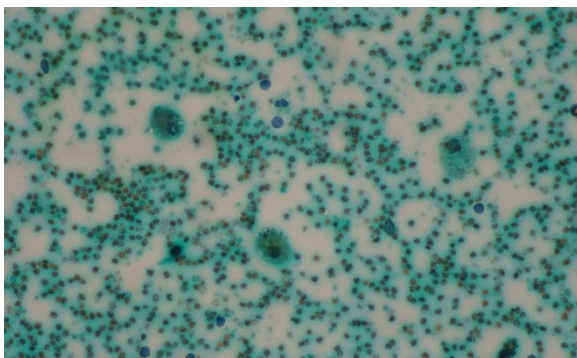


Figure 3: Follicular cells & lymphocytes in Thyroiditis

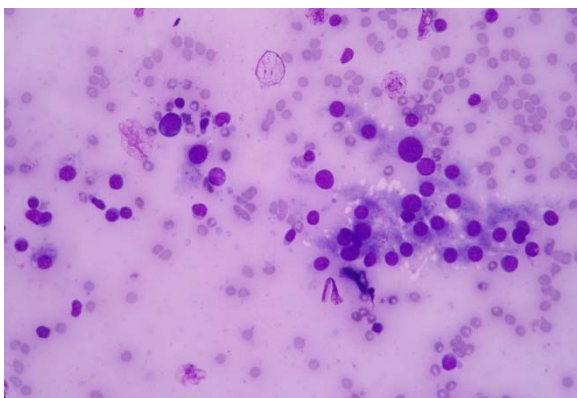
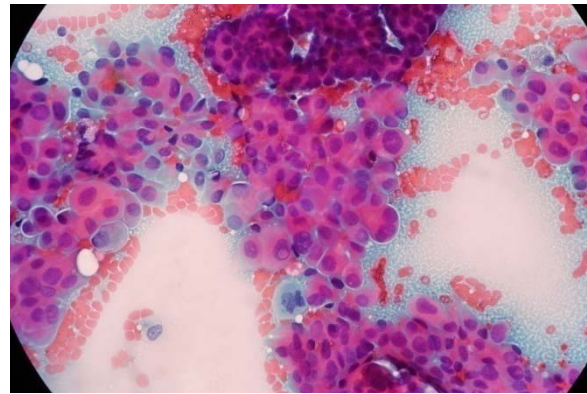


Figure 4: Cytology of Papillary carcinoma of thyroid



In these iodine-deficient areas, the incidence of goiter among thyroid nodules is much higher as shown in our study 111 out of 194 cases (57.22%) results are comparable to the study of Handa et al. which have similar results with incidence compared to present study. Thyroid diseases are not uncommon in our environment of study and being a referral hospital in Surat patients are referred for further management. Thyroid enlargement, whether diffuse or in the form of a nodule, leads to a battery of investigations, mainly to rule out the possibility of a neoplasm or thyroiditis. FNAC is usually the first line of investigation and other investigations like ultrasonography (USG) examination, thyroid function tests, thyroid scan, and antibody levels are done subsequently with an aim to select the patients who require surgery and those that can be managed conservatively.^{6, 7} The reasons may be due to the fact that not all thyroid lesions are subjected to surgery, many of the patients who had an initial FNAC never turn up for surgery and on the other hand some patients especially those operated from other hospitals and private clinics only send their lobectomy or thyroidectomy specimens for diagnosis. FNAC of the thyroid is widely used as it is safe, rapid, inexpensive, and reliable in the diagnosis of thyroid nodules.^{4, 5} The sensitivity of the thyroid FNAC ranges from 80 to 98% and its specificity from 58 to 100%.^{8, 9, 10, 11} The inadequacy rate in this study was 15 cases out of 194 (7.73 %). Previous studies have shown the percentage of inadequate material to vary between 0 and 25%.^{10, 11} Various studies have shown the role of USG guidance which can detect circumscribed lesions as small as 1 mm in diameter.^{12, 13} protocol in present study was to reaspirate under USG guidance which solved the problem in many cases. In addition, in mixed, solid-cystic lesions or difficult-to-palpate lesions, USG-guided aspiration technique is clearly superior to palpation-guided aspiration.¹⁴ The positive influence of FNAC on the management of thyroid disease is perhaps best highlighted in the low rate of surgical intervention. Surgery was avoided mainly in thyroiditis and in most of the cases of goitre which doesn't need cosmetic correction. Thus, FNAC can be used as an initial modality in the evaluation of palpable thyroid nodules

and helps in differentiating lesions that require surgery from those that can be managed otherwise. Published data suggest FNA has an overall accuracy rate around 75% in the detection of thyroid malignancy.¹⁵ The age group which was studied ranged from 6 months to 80 years and maximum no. of cases were in the age group 20-50 years. Most of thyroid diseases were frequently encountered in young and middle aged group also the majority of cases were the females in reproductive age groups. In present study a female preponderance was noted. Similar female preponderance was noted by Unnikrishnan et al.¹⁶ The most common cytological diagnosis was Colloid Goitre (57.22%) in present study. Similar findings were observed by Unnikrishnan et al.¹⁶ Goitre is one of the most common types of thyroid lesion in developing countries. Other diagnosis observed are Thyroiditis 45 cases (23.20%), Adenomatous goitre were 20 cases (10.31%), neoplastic lesions were 10 cases (5.15%), the benign cyst consistent with thyroglossal cyst were 4 cases (2.06%) and others were 4 cases (2.06%). Thus mainly nonneoplastic lesions with around 180 cases (92.78%) and neoplastic lesions were only 10 (5.15%). The bulk of the goitre cases were in the age group of 20-50 years and thyroiditis cases were in 11-40 years and mainly in the reproductive age group of the females. The chances of thyroiditis after reproductive age appeared minimal from this study. Menopausal women with increasing age were found to have more incidences of neoplastic and adenomatous cellular thyroid lesions. The benign cysts consistent with thyroglossal cysts were detected early. The results were comparable to other studies like Marwaha et al.¹⁷ This difference may be due to different study population, genetic factors, environmental factors and a hormonal effect which varies with age and gender. Majority of thyroid lesions were nodular at presentation with 117 cases whereas diffuse swelling was noted in 77 cases. Out of total 194 cases 74 cases were evaluated for assessment of hormonal status, 48 cases (64.86%) of them were found hyperthyroid and 19 cases (25.68%) were hypothyroid and 7 cases (9.46%) were euthyroid which generally thought to be due to genetic factors, environmental factors and hormonal effects and more number of hyperthyroid cases detected early during initial hyperthyroid phase. We here practiced mainly the non-aspiration technique in 175 cases for the aspiration of thyroid lesion and found that it is better than aspiration technique practiced in around 19 cases which yielded low cellularity and more blood as compared to non-aspiration method. We recommend the non-aspiration method for FNAC of thyroid lesions. Similar suggestions by different studies like Maurya et al.¹⁸ also recommend the non-aspiration technique better for thyroid lesion evaluation by FNAC. The study found that it is difficult to differentiate follicular/Hurthle cell adenoma from carcinoma on cytological assessment because cytology cannot evaluate the criteria of vascular or capsular invasion or of intrathyroid spread. But the papillary carcinoma, Anaplastic carcinoma and medullary carcinoma can be picked up by characteristic cytological features.

Marked cellularity of the smear is the problem inherent in thyroid FNAC. Increased cellularity of the smear and loss of cohesion may be present in hyperplastic/adenomatous goiter and follicular neoplasm which causes difficulty in differentiating them. This can be solved by using The Bethesda System of Reporting thyroid lesions. We experienced that The Bethesda Reporting System solves almost all the problems in diagnosing different thyroid lesions and answers to the queries. So we have started using the reporting system and we are strongly recommending it as a vital guide for accurate reporting of all the thyroid lesions which will guide the clinicians also regarding further management and maintain uniformity for communication among the pathologist, endocrinologist and treating clinicians.

So from the present study we can conclude that FNAC is the gold standard and first line of investigation in thyroid swellings which almost accurately guides for further management of thyroid swellings excluding the need for unnecessary other investigations and the most important from the treatment point of view the need of surgery in selected cases only because the majority of thyroid swellings are benign. Majority of thyroid swellings were due to goitre and thyroiditis and which are most prevalent in adolescent young patient and in females in reproductive age group. Regarding the FNA technique non-aspiration method is preferable and recommended. The Bethesda system of Reporting thyroid cytology is very helpful for maintaining effective communication among pathologist, endocrinologist and other treating clinicians providing vital guidance for further management so it is highly recommended to follow it. So according to us thyroid cytology should be reported using The Bethesda System of reporting to maintain uniformity.

REFERENCES

1. Tabaqchali MA, Hanson JM, Johnson SJ, Wadehra V, Lennard TW, Proud G. Thyroid aspiration cytology in Newcastle: a six year cytology/histology correlation study. *Ann R Coll Surg Engl.* 2000; 82(3):149-55.
2. Nggada HA and Khalil MIA. Fine Needle Aspiration Cytology (FNAC) Technique as a diagnostic tool of tumours in the UMTH, Nigeria. *Highland Medical Research Journal.* 2003; 1(3): 28-30.
3. Nasuti J, Gupta PK, Baloch ZW. Diagnostic value and cost-effectiveness of on-site evaluation of fine needle aspiration specimens: Review of 5,688 cases. *Diagn Cytopathology.* 2002; 27:1-4.
4. Silverman JF, West RE, Larkin EW, Park HM, Finley JL, Swanson MS et al. The role of FNAC in the rapid diagnosis and management of thyroid neoplasm. *Cancer.* 1986; 57: 1164-1170.
5. Kini U, Buch A, Bantwal G. Role of FNA in the medical management of minimally enlarged thyroid. *Diagn Cytopathol* 2006; 34:196-200.
6. Caruso D, Mazzaferri EL. Fine needle aspiration biopsy in the management of thyroid nodules. *Endocrinologist* 1. 1991: 194-202.

7. Giuffrida D, Gharib H. Controversies in the management of cold, hot and occult thyroid nodules. *Am J Med* 1995; 99:642-50.
8. DeMicco, Zoro P, Garcia S, Skoog L, Tani EM, Carayon P, *et al.* Thyroid peroxidase immunodetection as a tool to assist diagnosis of thyroid nodules on fine needle aspiration biopsy. *Eur J Endocrinol* 1994; 131:474-9.
9. La Rosa GL, Belfiore A, Giuffrida D, Sicurella C, Ippolito O, Russo G, *et al.* Evaluation of the fine needle aspiration biopsy in the preoperative selection of cold thyroid nodules. *Cancer* 1991; 67:2137-41.
10. Chang HY, Lin JD, Chen JF, Huang BY, Hsueh C, Jeng LB, *et al.* Correlation of fine needle aspiration cytology and frozen section biopsy in the diagnosis of thyroid nodules. *J Clin Pathol* 1997; 50:1005-9.
11. Gharib H, Goellner JR, Johnson DA. Fine needle aspiration cytology of the thyroid: A 12-year experience with 11,000 biopsies. *Clin Lab Med* 1993; 13:699-709.
12. Shenovi SR, Nadkarni NS, Wiseman RG. Role of fine needle aspiration cytology as initial modality in the investigation of thyroid lesions. *Acta Cytol* 1995; 39:898-904.
13. Carmesi C, Jeffrey RB, McDougall IR, Nowels KW, Weigel RJ. Ultrasound-guided fine needle aspiration biopsy of thyroid masses. *Thyroid* 1998; 8:283-9.
14. KojicKatovic S, Halbauer M, Tomic-Brzac H. Importance of FNAC in the detection of tumours within multinodular goiter of the thyroid. *Cytopathol* 2004; 15:206-11.
15. Robinson IA, Cozens NJ. Does a joint ultrasound guided cytology clinic optimize the cytological evaluation of head and neck masses? *Clin Radiol* 1999; 54:312-6.
16. Unnikrishnan et al: Endocrine Society of India management guidelines for patients with thyroid nodules: A position statement, *Indian J Endol Metab.* 2011 Jan-Mar; 15(1): 2–8.
17. Marwaha et.al: Hashimoto's Thyroiditis: Countrywide Screening of Goitrous Healthy Young Girls in PostiodizationPhase in India*: *Journal of Clin Endol Metab.* vol.85,2000.
18. Maurya et.al: Comparison of aspiration vs non-aspiration techniques in fine-needle cytology of thyroid lesions: *J Cytol.* April 2010, 27(2): 51–54.